
Document heading: Research Article

Pharmacological evaluation of *Allium cepa* extract as hepatoprotective potential in albino rat

Harikesh Maurya*

Hygia Institute of Pharmaceutical Education and Research, Prabhathi Nagar, Lucknow, India

Received: 15-10-2018 / Revised: 20-11-2018 / Accepted: 08-12-2018

Abstract

Objective: The study was designed to evaluate the hepatoprotective potential of *Allium cepa* extract in carbon tetrachloride (CCl₄) induced hepatotoxicity in albino rats. Methods: All albino rats were divided into four groups having six animal in each (n=6) to evaluate the efficacy of *Allium cepa* extract in comparison with standard drug Silymarin. The drugs were orally administered to rats for 10 days in CCl₄ model and animals were weighed periodically. At the end of the study, blood samples were collected for the test of SGOT, SGPT, ALP, total bilirubin, and total protein levels. The antioxidant enzyme parameters such as LPO, MDA, GSH, SOD, and CAT were also performed for all group of animal. The liver tissues of all groups were collected after scarifying the animals and histopathological examination reported for confirmation of potential activity. Results: All the test group of rats was significantly reduced levels of SGOT, SGPT, ALP, total bilirubin, in CCl₄ induced hepatotoxic models. There was a significant increase in total protein level in all the tested formulations. The antioxidant enzyme parameters such as LPO, MDA, GSH, SOD, and CAT were shows significant improvement in the treatment group as compared to disease control. The extract treated rats effectively preserved the structural integrity of the hepato-cellular membrane and liver cell architecture damaged by CCl₄. Conclusion: It can be concluded that the *Allium cepa* extract possesses hepatoprotective activity in CCl₄, induced hepatotoxicity in rats. This may be effectively used as a hepatoprotective agent in the management of hepatitis caused by various toxins.

Keywords: *Allium cepa*, Carbon tetrachloride, Hepatoprotective, Antioxidant enzyme.

Introduction

The liver is the important vital organ of the body plays a crucial role in the regulation of biological processes [1] such as metabolizing carbohydrates, lipids, proteins, and detoxifying xenobiotics and drugs. Thus it is liable to liver injury due to the chronic exposure of drugs, environmental toxicants, and other xenobiotics that causing serious health problems and affecting the cells, tissues, structures, and other hepatic functions [2].

The hepatic functions including metabolism, protein synthesis, or production of biochemical for digestion and breakdown of small or complex food particles essential for vital functions.

*Correspondence

Harikesh Maurya

Associate Professor, Department of Pharmacology,
Hygia Institute of Pharmaceutical Education and
Research, Prabhathi Nagar, Lucknow, India.

E-Mail: mauryaharikesh2@gmail.com

Nowadays, misuse of alcohol is one of the major health problems all over the World. It is well known that about 80% of ingested alcohol is metabolized in the liver so the close relationship between ethanol intake and alcoholic liver disease becomes common in youth [3,4].

Carbon tetrachloride (CCl₄) is one of the well-known hepatotoxins that widely used for induction of hepatotoxicity in the experimental animal. The main causes of CCl₄-induced liver damage our generation of free radicals, lipid peroxidation and decreased activities of antioxidant enzymes [5]. It is one of the major worldwide health problems like hepatitis and jaundice that observed about 20,200 deaths occurred every year due to the hepatic disease and excess consumption of alcohol [6,7].

The liver secretes bile into the intestine that utilizes in the digestion of dietary fat. The acute hepatotoxicity occurs due to the generation of free radicals that cause oxidative stress and membrane damage leads to hepatocellular damage and enhances formation of inflamed tissues because of lipid peroxidation [8]. The

rise in serum levels of AST, ALT, and cholesterol has been attributed to the damaged hepatic structural integrity since they are cytoplasmic in location and released into circulation after cellular damages [9].

Generally, herbal drugs or ayurvedic preparation are highly used for management of liver disorder than allopathic drugs, because the liver plays an important role in the clearance of toxins from the body [10,11]. Several herbal medicines are claimed to assist in the healthy standard of living and play a significant involvement in the management of hepatotoxicity [12]. *Allium cepa* (onion) belonging to the family-Liliaceae, widely cultivated with mass production in China, India and the United States. Onion contains proteins, carbohydrates, sodium, potassium, and phosphorus played a crucial role in the treatment of intestinal infections, eye infections, earache, urinary tract burning, headaches associated with drowsiness, heel ulcers and cough from the cold air inspiration. Many reports revealed that onion possesses antibacterial, antiviral, antiparasitic, antihypertensive, anti-hypoglycemic, antithrombotic, antihyperlipidemic, anti-inflammatory, antifungal and antioxidant activities [13].

Recently, the extracts of various parts of the *A. cepa* have been extensively studied for their anti-diabetic, anti-tumor, hepatoprotective, and anti-nephrotoxicity activities [14-17]. However, the protective roles of aqueous extract of *A. cepa* bulb well known as a culinary agent, in keeping these folkloric claims and view reports, the present study was designed to evaluate the hepatoprotective potential of *Allium cepa* extract in carbon tetrachloride (CCl₄) induced hepatotoxicity in albino rats.

Materials and methods

Experimental animals: Albino Wister rats weighed 150-180g was used for the study, all animals were maintained under standard laboratory conditions with the dark and light cycle at a temperature (25°C) and humidity 55-60%. Rats were housed in separate cages containing 6 animals in each acclimatized for one week. The animal was randomized into experimental and control groups and housed individually in sanitized polypropylene cages containing sterile paddy husk as bedding. The animal was habituated to laboratory conditions for 48 hr and provided daily diet and water. All the procedures and protocols used in the study were approved by the Institutional Animal Ethical Committee clearance and follow the CPCSEA guidelines.

Drug and chemicals: CCl₄, Silymarin (Ranbaxy Pvt. Ltd.) were purchased from local supplier Lucknow for the experimental purpose. All the reagents used were of analytical grade. Biochemical estimation kits (Span Diagnostic) were used for serum glutamine pyruvate transaminase (SGPT), serum glutamine oxaloacetate transaminase (SGOT), alkaline phosphatase (ALP), total bilirubin and total protein estimation.

Preparation of extract: The shade dried onion was crudely powdered by using a mechanical grinder then weigh and mixed in purified water in a beaker to perform extraction by cold maceration technique. After that extract was concentrated under vacuum evaporator and the dried extract was obtained. The dry onion extract was dissolved in distilled water to make in solution form before oral administration.

Preliminary Phytochemical analysis: Onion was subjected to preliminary phytochemical screening for the detection of the presence of various phytoconstituents like alkaloid, tannin, saponin, phenolics etc [18].

Experimental design: Then all the animals were randomized into 4 groups having 6 animals in each group. Group I served as normal control received normal saline for 10 days. Group II rats were administered i.p. a 1.5ml mixture of carbon tetrachloride in olive oil (1:1) last two days for the induction of hepatotoxicity. Group III animal received Silymarin 50mg/kg for every day and 1.5 ml CCl₄ in olive oil at 9th and 10th day of the experiment. Group IV rats received onion extract at a dose of 200 mg/kg every day and 1.5 ml CCl₄ in olive oil on the 9th and 10th day of the experiment. Blood samples were taken by a retro-orbital puncture at the end of study for biochemical analysis and liver tissue also collected for histological analysis.

Estimation of biochemical markers: After 24 h of the last administered dose, the rats were anesthetized using ether and blood sample was collected by retro-orbital puncture method and serum was separated for the estimation of biochemical parameters. The liver function test such as SGPT, SGOT, alkaline phosphate, bilirubin, and total protein was determined in each blood sample. After that, the rats were sacrificed by cervical dislocation for the collection of liver tissue to analyze histological parameters. The biochemical parameters were properly estimated with the standard procedure by using the diagnostics kits [19].

Histopathological examination: The liver was taken out from sacrificed rat and weighed accurately then cut into small pieces. The liver was washed with normal saline and preserved in formalin solution (10%). After fixation, processing of livers was done with the routine histopathologic procedure and embedded in paraffin wax. Several 4-5 μm sections of each liver blocks were stained with hematoxylin and eosin. The sections were examined under a high-resolution electron microscope [20].

Antioxidant activity: The level of lipid peroxidation (LPO) was estimated and expressed in terms of malondialdehyde (MDA) as per the method of Ohkawa *et al.* 1979 [21]. The activity of superoxide dismutase (SOD) was estimated as per the procedure of Kakkar *et al.* (1984) [22] based on the reduction of NBT to blue colored formazan in presence of phenazine

methosulfate. The levels of glutathione (GSH) and catalase (CAT) were expressed as $\mu\text{mol/g}$ of wet tissue after estimation as per the method of Sedlak and Lindsay, 1968 [23].

Statistical analysis: All results are expressed as mean \pm SEM ($n=6$). Statistical comparison was done by one-way ANOVA, followed by the Bonferroni-compare selected pairs of the column using Graph Pad Prism Software Version 5.01 (Fay Avenue, La Jolla, CA, USA).

Results

Preliminary phytochemical analysis

Preliminary phytochemical screening shows the presence of carbohydrates, flavonoids, tannins, saponins, steroids in the aqueous extract of onion bulb (Table 1).

Table 1: Phytochemical analysis of the aqueous extract of *Allium cepa* bulb

Phytoconstituents	Inference
Carbohydrates	+
Flavonoids	+
Proteins	-
Glycosides	-
Saponin	+
Fats and oils	-
Alkaloids	-
Steroids	+
Tannins	+

+: Present, -: Absent

Effect on biochemical levels

The animals treated with CCl_4 (1.5 ml/kg) showed significant ($^{\#}P<0.05$) increase in the level of serum enzymes SGPT, SGOT, and ALP when compared to the normal control group. The animals treated with silymarin as well as onion extract 200 mg/kg showed significant ($^*P<0.05$) improvement in the level of SGPT, SGOT and ALP when compared to the CCl_4 treated group. Onion extract 200 mg/kg showed highly significant ($^*P<0.05$) improvement in the level of serum enzymes SGPT, SGOT, and ALP when compared to the disease control as well as standard treatment groups (Table 2).

The animals treated with CCl_4 showed significant ($^{\#}P<0.05$) increase in the level of total bilirubin as compared to the normal control group. The animals treated with silymarin, as well as onion extract 200 mg/kg showed significant ($^*P<0.05$) improvement in these elevated levels as compared to the disease control. In the case of total protein the rat treated with CCl_4 showed very minute reduction as compared to normal control. After oral administration of the test and standard drug the elevated parameter was completely subsided (table 2).

Table 2: Observation of biochemical parameters in experimental animals

Groups	SGPT (IU/L)	SGOT (IU/L)	ALP (IU/L)	Total bilirubin (mg/dl)	Total protein (g/dl)
Normal control	53.88±2.08	175.31±3.81	375.52±4.16	0.26±0.08	6.22±0.28
Disease control	113.10±3.50 [#]	248.26±4.57 [#]	446.35±5.90 [#]	0.57±0.07 [#]	5.10±0.22 [#]
CCl ₄ +Silymarin	68.75±2.48 [*]	193.51±3.90 [*]	403.47±4.70 ^{NS}	0.40±0.05 ^{NS}	5.68±0.35 ^{NS}
CCl ₄ +Onion extract	62.98±2.77 [*]	183.08±3.05 [*]	380.43±3.90 [*]	0.33±0.08 [*]	6.16±0.40 [*]

Values are expressed as Mean±SEM (n=6); [#]P<0.05 considered as statistically significant against normal control. ^{*}P<0.05 considered as statistically significant against disease control and NS shows statistically non-significant.

In vivo Antioxidant Activity

The animal treated with CCl₄ showed significant ([#]P<0.05) increase level of LPO and MDA as compared to the normal control group. The dose of onion extract 200 mg/kg showed significant (^{*}P<0.05) reduction in these elevated levels as compared to disease control and the standard treatment group. The Silymarin treated group also showed significant (^{*}P<0.05) improvement in the level of LPO and MDA as compared to disease control. On the other hand, the

GHS, SOD and CAT activity showed significant ([#]P<0.05) reduction of these level in the animal treated with the CCl₄ as compared to the normal control. After oral administration of onion extract, 200 mg/kg showed significant (^{*}P<0.05) improvement in the elevated levels of GHS, SOD, and CAT as compared to disease control and standard control. The Silymarin treated group also showed significant (^{*}P<0.05) improvement in these levels as compared to disease control (Table 3).

Table 3: Observation of antioxidant enzyme parameters in experimental animals

Groups	LPO (nmol/mg protein)	MDA (nmol/mg protein)	GSH (nmol/mg protein)	SOD (µg/mg protein)	CAT (µg/mg protein)
Normal control	0.05±0.02	0.82±0.03	2.54±0.08	52.20±4.65	15.41±1.08
Disease control	0.12±0.06 [#]	4.23±1.00 [#]	0.58±0.03 [#]	11.87±2.00 [#]	03.72±2.05 [#]
CCl ₄ +Silymarin	0.03±0.05 [*]	1.22±0.06 [*]	2.10±0.05 [*]	47.18±4.20 [*]	12.88±2.82 [*]
CCl ₄ +Onion extract	0.04±0.04 [*]	0.98±0.08 [*]	2.38±0.12 [*]	49.02±4.32 [*]	14.00±3.00 [*]

Values are expressed as Mean±SEM (n=6); [#]P<0.05 considered as statistically significant against normal control and ^{*}P<0.05 considered as statistically significant against disease control.

Histopathology of liver

The histological study of liver tissue shows that the hepatic cells were normal in shape and size with the prominent nucleus of the rat in the normal group. The cord-like arrangement of liver cells was separated by sinusoids and central vein are also clearly visible in the normal group. In CCl₄ treated group shows the structural design of the liver was totally damaged by means of cell lysis, scattered sinusoids, and aggregation of nuclei visible at some places as compared to normal rats. Prominent cell vacuolation,

pyknotic and degenerated nuclei along with damaged bile capillaries were also observed in disease control. These cellular changes were significantly reduced in CCl₄+Silymarin treated groups with several normal hepatocytes interspersed and patches of mild necrosis were observed. The hepatic cells of rats treated with CCl₄+Onion extract 200mg/kg showed the clear nucleus, cell vacuolation, endothelium, and normal hepatocytes. The overall structural design of the hepatic cells appears to be normal in the treatment group (Fig.1).

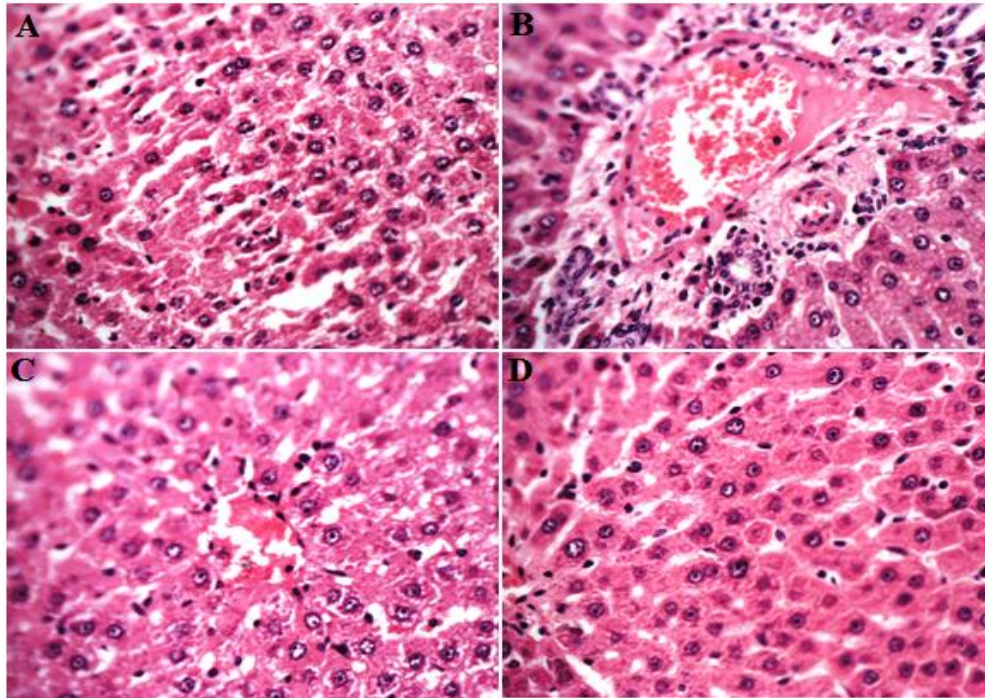


Figure 1: Photomicrographs of liver sections reported as (a) Normal control group-Normal central vein, vacuolation, steatosis and lymphocytes; (b) Carbon tetrachloride (CCl₄)-Degenerated nuclei, sinusoidal dilatation, inflammatory infiltration, vacuolation and steatosis; (c) CCl₄+Silymarin-Central vein, sinusoidal dilatation, vacuolation, steatosis and infiltration of lymphocytes observed; (d) CCl₄+Onion extract-Normal sinusoid, vacuolation, steatosis and lymphocytes.

Discussion

Globally the liver diseases become a serious health problem because of the deficient of helpful therapeutic approach. Several medicinal plants that are used as a hepatoprotective science ancient time as traditional medicine systems play a crucial role in fairly resolving this situation [24]. Thus it becomes necessary to assess the scientific basis for the reported hepatoprotective activity of herbal drugs in a pharmaceutical dosage form. In this concern, I have a design to evaluate of *Allium cepa* extract as hepatoprotective potential against CCl₄ induced liver toxicity in rats.

The scientific studies reported that CCl₄ is metabolically activated by Cytochrome P450-dependent mono-oxygenase to form highly reactive free radical metabolites, tri-chloro-methyl free radical (CCl₃·) which later convert into more toxic trichloro-methyl peroxy radical (CCl₃OO·) in presence of oxygen. The same is capable to produce a disturbance in the transport function of the hepatocytes which leads to leakage of enzymes (SGOT and SGPT) from cells, hyperbilirubinemia and increase in the level of serum ALP [25]. The result of the present study reveals that

the animal treated with onion extract antagonizes these elevated enzymes. The tendency of these enzymes reached to the normal range after administration of extract clearly indicating that the onion extract 200 mg/kg has been challenged to protect liver tissue from CCl₄ intoxication. It was reported and accepted that serum levels of SGOT and SGPT return to normal with the healing of liver parenchyma and the regeneration of hepatocytes [26].

The rats treated with CCl₄ observed a significant decrease in hepatic enzymes GSH, SOD, and CAT as antioxidant markers. Subsequently, the reduction in free radicals generation is a possible mechanism in the defense of the liver against different injuries. In this study dramatic increase in LPO and MDA after CCl₄ treatment suggested that natural antioxidant defense mechanism to scavenge excessive free radicals has been compromised. The treatment with onion extract significantly inhibited the formation of MDA and LPO in liver tissue [27]. These antioxidant enzymes are involved in the reduction of ROS and peroxidase produced in the living organism thus play a vital role in the maintenance of a balance redox status. The

restoration of the SOD towards a normal value indicates that the *A. cepa* extract can help in cellular defense mechanisms by preventing cell membrane oxidation [28].

The experiential hepatoprotective activity of the onion extract may be on account of the presence of polyphenolic compounds found in the preliminary phytochemical screening (Table 1) as these compounds are reported to have the free radical scavenging ability, which stabilizes lipid oxidation. Flavonoids correspond to a group of polyphenolic compounds, which exhibits a wide range of biological activities primarily due to their antioxidant property, probably because of their free radical scavenging activity and ability to reduce free radical formation [29]. The reported studies suggest a correlation between phenolic content and hepatoprotective activities. Saponins and steroids present in the onion extract are also effective against hepatotoxins induced by CCl₄ [30,31].

The histological studies confirm the curative efficacy of *Allium cepa* extract against CCl₄ induced hepatic damage. Vacuolated hepatocytes along with fatty deposition, necrosis, and degenerative changes were observed in the CCl₄ group. This could be due to the formation of highly reactive free radicals because of oxidative stress caused by CCl₄ [32]. Results showed improvement in metabolic activity and cellular stability. On the whole hepatoprotective effect of *Allium cepa* extract is most likely due to the antioxidant properties. This data provide a primary base for the treatment and management of hepatic disorders.

Conclusion

The Significant hepatoprotective potential of onion extract (*Allium cepa*) was observed in the present investigation which could result from potentiating the action of its phytoconstituents since they contain a diverse array of active principles able to target multiple mechanisms involved in the hepatoprotective activity. The mechanism of the hepatoprotective action of these extracts is uncertain but may be related to the ability of the plant to inhibit lipid peroxidation in the liver. The high flavonoid content explains its role as hepatoprotective by inhibiting the free radicals mediated damage.

Acknowledgment

I am very thankful to the Director of Hygia Institute of Pharmaceutical Eructation and Research, Prabandh Nagar, Lucknow (UP) India for providing such type of facilities to do my research work peacefully.

References

1. Bhatia SN, Underhill GH, Zaret KS, Fox IJ. Cell and tissue engineering for liver disease. *Science Translational Medicine* 2014;6(245):245sr2.
2. Kumar KE, Harsha KN, Sudheer V, babu NG. *In vitro* antioxidant activity and *in vivo* hepatoprotective activity of aqueous extract of *Allium cepa* bulb in ethanol induced liver damage in Wistar rats. *Food Science and Human Wellness* 2013;2:132–138.
3. Ilyas U, Katare DP, Aeri V, Naseef PP. A review on hepatoprotective and Immunomodulatory herbal plants. *Pharmacognosy Review* 2016;10(19):66-70.
4. Gu X, Manautou JE. Molecular mechanisms underlying chemical liver injury. *Expert Reviews in Molecular Medicine* 2012;14:e4.
5. El-Meligy RM, Zain ME, Ahmed FA. Protective role of *Cynanchum acutum* L. extracts on carbon tetrachloride-induced hepatotoxicity in rat. *International Journal of Chemical and Applied Biological Sciences* 2014;1(1):8-13.
6. Chung RT, Stravitz RT, Fontana RJ, Schiodt FV, *et al.* Pathogenesis of liver injury in acute liver failure. *Gastroenterology*. 2012;143(3):e1-e7.
7. Marudanayagam R, Shanmugam V, Gunson B, Mirza DF, *et al.* Aetiology and outcome of acute liver failure. *HPB (Oxford)* 2009;11(5):429-34.
8. Malhi H, Gores GJ. Cellular and molecular mechanisms of liver injury. *Gastroenterology* 2008;134(6):1641-54.
9. Shrivastava S, Gilhotra R. Hepatoprotective potential of polyherbal preparation against CCl₄-induced liver toxicity in rats. *International Journal of Pharmaceutical Science and Research* 2017;8(3):1498-03.
10. Teschke R, Frenzel C, Glass X, Schulze J, *et al.* Herbal hepatotoxicity: a critical review. *British Journal of Clinical Pharmacology* 2013;75(3):630–636.
11. Madrigal-Santillán E, Madrigal-Bujaidar E, Álvarez-González I, Sumaya-Martínez MT, *et al.* Review of natural products with hepatoprotective effects *World Journal of Gastroenterology* 2014;20(40):14787–804.
12. Manoj S, Mohanty PK, Jaliwala YA. Hepatoprotective activity of fruits of *Prunus domestica*. *International Journal of Pharma and Bio Sciences* 2011;2:439–453.
13. Griffiths G, Trueman L, Crowther T, Thomas B, *et al.* Onions-A global benefit to health. *Phytotherapy Research* 2002;16(7):603-15.
14. Kook S, Kim GH, Choi K. The antidiabetic effect of onion and garlic in experimental diabetic rats: a meta-analysis. *Journal of Medicinal Food* 2009;12:552–556.

15. Dorant E, Van den Brandt PA, Goldbohm RA. A prospective cohort study on the relationship between onion and leek consumption, garlic supplement use and the risk of colorectal carcinoma in The Netherlands. *Carcinogenesis* 1996;17:477-484.
16. Obioha UE, Suru SM, Ola-Mudathir KF, *et al.* Hepatoprotective potentials of onion and garlic extracts on cadmium-induced oxidative damage in rats. *Biological Trace Element Research* 2009; 129:143-156.
17. Ige SF, Akhigbe RE, Adewale AA, *et al.* Effect of *Allium cepa* (onion) extract on cadmium-induced nephrotoxicity in rats. *Kidney Research Journal* 2011; 1:41-47.
18. Laloo D, Sahu AN, Hemalatha S, Dubey SD. Pharmacognostical and phytochemical evaluation of *Cinnamomum wightii* Meissn flowers. *Indian Journal of Natural Products and Resources* 2012;3:33-9.
19. Singh NK, Sahu AN, Singh SK. Free radical scavenging and hepatoprotective activities of Standardized methanolic extract of *Maydis stigma*. *Pharmacology online* 2009;2:440-9.
20. Sridevi VK, Chouhan HS, Singh NK, Singh SK. Antioxidant and hepatoprotective effects of ethanol extract of *Vitex glabrata* on carbon tetrachloride-induced liver damage in rats. *Natural Product Research* 2012;26:1135-40.
21. Ohkawa H, Ohishi N, Yagi K. Assay for lipid peroxides in animal tissues by thiobarbituric acid reaction. *Analytical Biochemistry* 1979;95:351-8.
22. Kakkar P, Das B, Viswanathan PN. A modified spectrophotometric assay of superoxide dismutase. *Indian Journal of Biochemistry and Biophysics* 1984;21:130-2.
23. Sedlak J, Lindsay RH. Estimation of total, protein-bound, and nonprotein sulfhydryl groups in tissue with Ellman's reagent. *Analytical Biochemistry* 1968;25:192-205.
24. Chandan BK, Saxena AK, Shukla S, Sharma N, *et al.* Hepatoprotective activity of *Woodfordia fruticosa* Kurz flowers against carbon tetrachloride induced hepatotoxicity. *Journal of Ethno pharmacology* 2008;119:218-24.
25. Bera TK, Chatterjee K, De D, Ali KM, *et al.* Hepatoprotective activity of livshis, a polyherbal formulation in CCl₄-Induced hepatotoxic male Wistar rats: A toxicity screening approach. *Genomic Medicine, Biomarkers, and Health Sciences* 2011;3:103-10.
26. Osadebe PO, Okoye FB, Uzor PF, Nnamani NR, *et al.* Phytochemical analysis, hepatoprotective and antioxidant activity of *Alchornea cordifolia* methanol leaf extract on carbon tetrachloride-induced hepatic damage in rats. *Asian Pacific Journal of Tropical Medicine* 2012;5:289-93.
27. Qu L, Xin H, Zheng G, Su Y, Ling C. Hepatoprotective Activity of the Total Saponins from *Actinidia valvata* Dunn Root against Carbon Tetrachloride-Induced Liver Damage in Mice. *Evidence-Based Complementary and Alternative Medicine* 2012;2012:216061.
28. Lima TB, Suja A, Jisa OS, Sathyanarayanan S, *et al.* Hepatoprotective activity of LIV-first against carbon tetra chloride-Induced hepatotoxicity in albino rats. *International Journal of Green Pharmacy* 2010;4:71-4.
29. Wu Y, Wang F, Zheng Q, Lu L, *et al.* Hepatoprotective effect of total flavonoids from *Laggera alata* against carbon tetrachloride-induced injury in primary cultured neonatal rat hepatocytes and in rats with hepatic damage. *Journal of Biomedical Science* 2006;13:569-78.
30. Awaad AS, Soliman GA, El-Sayed DF, El-Gindi OD, *et al.* Hepatoprotective activity of *Cyperus alternifolius* on carbon tetrachloride-induced hepatotoxicity in rats. *Pharmaceutical Biology* 2012;50:155-61.
31. Afzal M, Khan R, Kazmi I, Anwar F. Hepatoprotective potential of new steroid against carbon tetrachloride-induced hepatic injury. *Molecular and Cellular Biochemistry* 2013;378:275-81.
32. Yang CC, Fang JY, Hong TL, Wang TC, *et al.* Potential antioxidant properties and hepatoprotective effects of an aqueous extract formula derived from three Chinese medicinal herbs against CCl₄-induced liver injury in rats. *International Immunopharmacology* 2013;15:106-13.

Source of Support: Nil

Conflict of Interest: Nil