

Diagnostic Utility of ADC Value of the Spleen in Assessing Severity of Portal Hypertension in Cirrhosis of Liver

Himanshu Kumar Bhaiya¹, Smita Priyadarshini^{2*}

¹Assistant Professor, Department of Medicine, Sheikh Bhikari Medical College, Hazaribag, Kolghati, Hazaribag, India

²Assistant Professor, Department of Medicine, Sheikh Bhikari Medical College, Hazaribag, Kolghati, Hazaribag, India

Received: 03-04-2021 / Revised: 04-05-2021 / Accepted: 08-06-2021

Abstract

Introduction: Chronic liver disease is a major spectrum of disease due to various aetiologies and portal hypertension (PH) is an essential manifestation of end-stage liver disease. However, accurate evaluation of PH severity and its management depends on invasive investigations like repeated upper gastrointestinal endoscopy and hepatic venous wedge pressure monitoring. **Materials and methods:** This prospective descriptive study was performed in our hospital from January 2020 to December 2020 on consecutive chronic liver disease patients referred to our Medicine Department. As this study is the first of its kind done on portal hypertension patients, we initially planned to find out any difference and the characteristics of the MRI (DWI) spleen findings of chronic liver disease/ cirrhosis patients compared to a control group with no liver disorders. For control, patients who undergo MRI abdomen investigation for other reasons with normal liver function test were included and were analysed. **Results:** We initially compared 15 patients from each group (Case and control) to analyse the difference in MRI findings of the spleen in DWI. We analysed the demographics of both groups and found to be matched with no significant difference between the age and sex of the patients (Median age 43 vs. 42, p= 0.9, sex 12 vs. 15 males, p= 0.6). When the clinical and biochemical parameters were compared between the two groups, there were obviously significant differences in parameters of chronic liver disease like hypersplenic features, liver span, spleen span and serum bilirubin, serum creatinine and INR. **Conclusion:** In conclusion, our results show that spleen ADC values vary among patients with liver cirrhosis and control subjects. Furthermore, ADC values in the spleen correlated well with the severity of portal hypertension and not significantly with the degree of liver disease. Thus, the spleen might only be of limited value for normalization of liver ADC values to determine cirrhosis. ADC measurements may allow for non-invasive evaluation of portal pressure and even in assessment of treatment response.

Keywords: Chronic liver disease, ADC, DWI, MRI, PH.

This is an Open Access article that uses a fund-ing model which does not charge readers or their institutions for access and distributed under the terms of the Creative Commons Attribution License (<http://creativecommons.org/licenses/by/4.0>) and the Budapest Open Access Initiative (<http://www.budapestopenaccessinitiative.org/read>), which permit unrestricted use, distribution, and reproduction in any medium, provided original work is properly credited.

Introduction

Chronic liver disease is a major spectrum of disease due to various aetiologies and portal hypertension (PH) is an essential manifestation of end-stage liver disease. However, accurate evaluation of PH severity and its management depends on invasive investigations like repeated upper gastrointestinal endoscopy and hepatic venous wedge pressure monitoring[1]. Recently, magnetic resonance imaging (MRI) has been used increasingly in the evaluation of cirrhotic patients, more for cancer evaluation and surveillance. Diffusion weighted imaging (DWI) and MRI elastography (MRE) were used for assessing the degree of liver fibrosis[3,4]. However, very few studies have assessed the MRI characteristic of the spleen and its haemodynamics in cirrhosis and portal hypertensive patients [5,6]. The primary objective of this study is to analyse the correlation of ADC value of the spleen in chronic liver disease patients, to the severity of portal hypertension in the form of clinically significant portal hypertension (CSPH) and also the surrogate markers of portal hypertension in the form of grade of oesophageal varices, incidence of gastrointestinal (GI) bleeds, hypersplenism and size of the spleen. We also tried to analyse the correlation of the spleen and liver ADC

to the severity of cirrhosis in terms of Child-Turcotte-Pugh's class (CTP) and model for End-Stage Liver Disease (MELD) score[9].

Materials and Methods

This prospective descriptive study was performed in our hospital from January 2020 to December 2020 on consecutive chronic liver disease patients referred to our Medicine Department. As this study is the first of its kind done on portal hypertension patients, we initially planned to find out any difference and the characteristics of the MRI (DWI) spleen findings of chronic liver disease/ cirrhosis patients compared to a control group with no liver disorders. For control, patients who undergo MRI abdomen investigation for other reasons with normal liver function test were included and were analysed. Patients admitted with clinical and examination findings of chronic liver disease/cirrhosis were evaluated with detailed history. Their investigations were reviewed to confirm the aetiology, evidence of hypersplenism (haemoglobin, white blood cell count and platelet count), CTP class and MELD score to assess the severity of chronic liver disease. Upper gastrointestinal endoscopy findings of the patient done at the initial visit or the highest grade of the oesophageal varices were noted along with sonographic findings of the size and echotexture of the liver along with spleen size, portal vein diameter and grade of ascites (no/moderate/severe). Patients were analysed before starting treatment for portal hypertension, as this might be a confounding variable on the ADC value. Finally, the patients were subjected for MRI examination after informed consent. The study was done in a 1.5-tesla MRI scanner (Siemens Magnetom

*Correspondence

Dr.Smita Priyadarshini

Assistant Professor, Department of Medicine, Sheikh Bhikari Medical College, Hazaribag, Kolghati, Hazaribag, India

E-mail: smita.priyadarshinee@gmail.com

Symphony) with b value of 0, 300 and 500 for DWI. Routine T1W1, T2W1 and in phase/ opposed phase imaging was done as part of protocol. Slice thickness of 5 mm, matrix size of 256 * 256 were used. ADC value of the spleen along with liver was calculated. Clinically significant portal hypertension (CSPH) was defined as the presence of either oesophageal or gastric variceal bleed, portal hypertensive gastropathy or thrombocytopenia (platelet count < 100000/cu.mm) associated with splenomegaly. Oesophageal varices were graded according to Conn's classification[10]. Hypersplenism was defined as the presence of splenomegaly with a defect in any one of the peripheral cell lines (anaemia- haemoglobin less than 8 gm/dL with normocytic and normochromic appearance in peripheral smear; a leukocyte count of <3500/cu.mm and a platelet count of <150000/cu.mm. Degree of splenomegaly was classified using

Hackett's classification. The severity of hepatic encephalopathy is graded with the "West Haven" criteria.

Statistical analysis was done using SPSS ver. 17. Student's 't' test was used in the comparison of numerical variables (mean ages, liver size, spleen size, PV diameter, laboratory values, liver and spleen ADC values) between the patient group and the control group. ANOVA was used in comparison of CTP class and MELD score to the ADC value of the patients. Again student's 't' test was used in comparison of the ADC value of the patient to different portal hypertension surrogate markers, degree of liver fibrosis and CSPH. Differences were considered to be statistically significant at $p < 0.05$.

Results

Table 1: Mean ADC Spleen and Liver (mm²/s) - Case vs. Control

Variables	Case (30)	Control (30)	P Value
ADC Liver (mm ² /s)	107.2±41.8	338.9±31.1	0.001
ADC (mm ² /s)	117.4±28.4	80.7±9.1	0.004

Table 2: Correlation between Mean ADC value of Spleen and Liver to Clinically Significant Portal Hypertension (CSPH)

Variables	ADC Spleen(mm ² /s)	ADC Liver(mm ² /s)
CSPH (39)	125.2±29.6	89.2±20.1
No CSPH (12)	84.1±1.6	134.3±11.4
P Value	0.05	0.09

Table 3: Mean ADC of the Spleen and Portal Hypertension Surrogate Markers

Portal Hypertension Surrogates	ADC Spleen (mm ² /s)	P Value
Bleeder (32) vs. Non-bleeder (19)	120.2±28.6 vs 86.1±1.6	0.06
Grade of Oesophageal Varices (<= 2 vs. > 2)	93.1±9.9 vs 126.6±20.2	0.04
Symptomatic Hypersplenism (19) vs. Asymptomatic Hypersplenism (32)	123.3±23.1 vs 90.2±11.3	0.02
PV Diameter(<= 13 mm vs. > 13 mm)	112.3±23.1 vs 123.3±8.9	0.12
Splenomegaly (<= 13 cm vs. > 13 cm)	109.5±9.1 vs 123.4±7.8	0.23

Table 4: Mean ADC Spleen/ Liver vs. Child-Pugh Class Status

Child Pugh Class	ADC Liver (mm ² /s)	ADC Spleen (mm ² /s)
A	140.1±13.4	85.9 ± 9.4
B	120.2±11.3	101.4±11.4
C	82.0±9.3	121.6±14.2
P Value	0.05	0.12

Table 5: Mean ADC Spleen/ Liver vs. Model for End-Stage Liver Disease (MELD)

MELD	ADC Liver (mm ² /s)	ADC Spleen (mm ² /s)
>15	135.1±11.4	89.9±9.4
16-25	113.2±16.3	99.4±11.4
>25	83.9±10.3	127.6±14.2
P Value	0.04	0.09

ADC Spleen- Control vs. Chronic Liver Disease Patients

We initially compared 15 patients from each group (Case and control) to analyse the difference in MRI findings of the spleen in DWI. We analysed the demographics of both groups and found to be matched with no significant difference between the age and sex of the patients (Median age 43 vs. 42, $p = 0.9$, sex 12 vs. 15 males, $p = 0.6$). When the clinical and biochemical parameters were compared between the two groups, there were obviously significant differences in parameters of chronic liver disease like hypersplenic features, liver span, spleen span and serum bilirubin, serum creatinine and INR.

ADC Characteristics of the Spleen and Liver- Case vs. Control

When the ADC value (mm²/s) of the spleen and liver were analysed between the case and control group, we found ADC value of the spleen increased (117.4 ± 28.4 vs. 80.7 ± 9.1, $p = 0.04$) significantly in chronic liver disease patients, whereas ADC value of the liver significantly decreased (107.2 ± 41.8 vs. 338.9 ± 31.1, $p = 0.001$) in the same group, (Table-1).

ADC Spleen and Chronic Liver Disease

We analysed the 51 chronic liver disease patients of various aetiologies managed in our hospital from January 2017 - October 2017. Out of the 51 chronic liver disease patients, most of them belonged to CTP class A (29/51) status with 9 patients of CTP class C status. Their mean age was 49.6 ± 12.3 years with 38 of them males. Most of them had hypersplenism with their mean haemoglobin of 8.42 ± 2.1 gms %, mean WBC count of 5820 ± 1720/ cu.mm and mean platelet count of 100313 ± 25189/ cu.mm. Out of the 51 patients, 32 patients were bleeders with 4 patients having grade 4 varices. Their median MELD score was 11.

ADC of the Spleen with Severity of Portal Hypertension

We analysed the ADC mapping of the spleen for the 51 patients and compared it between the 39 patients who had clinically significant portal hypertension (CSPH) to the group of 12 patients who had no CSPH. We found the ADC value of the spleen was significantly higher (125.2 ± 29.6 vs. 84.1 ± 1.6, p value = 0.05) in the CSPH

group; however, the ADC value of the liver is non-significantly lower (84.1 ± 1.6 vs. 125.2 ± 29.6 , p value= 0.09) in the CSPH group compared to the non-CSPH group, Table 2.

ADC of the Spleen and Portal Hypertension Surrogate Markers

We also analysed the ADC value of the spleen with the different portal hypertension surrogate markers and found that though ADC of the spleen was non-significantly higher in the presence of increased severity of portal hypertension, it is the oesophageal varices > grade 2 and symptomatic hypersplenism which had significantly higher spleen ADC compared to the other group, Table 3.

ADC Spleen and Liver vs. CTP Class Status

As evaluated in the past studies, we also analysed the ADC value of the spleen and liver for different CTP class patients and found that as the CTP class worsens, the ADC value of the liver decreased (140.1

± 13.4 vs. 120.2 ± 11.3 vs. 82.0 ± 9.3 , p value= 0.05), which was statistically significant. However, though the ADC of the spleen increased proportionately to the CTP class (85.9 ± 9.4 vs. 101.4 ± 11.4 vs. 121.6 ± 14.2 , p -value= 0.12), it was not statistically significant, Table 4.

ADC Spleen and Liver vs. Model for End-Stage Liver Diseases (MELD)

We in addition analysed the ADC value of the spleen and liver to different levels of MELD score and again found that the ADC value of the liver significantly decreased (135.1 ± 11.4 vs. 113.2 ± 16.3 vs. 83.9 ± 10.3 , p value= 0.04) according to the increasing MELD score. Here also the ADC of the spleen was non-significantly increasing (89.9 ± 9.4 vs. 99.4 ± 11.4 vs. 127.6 ± 14.2 , p value= 0.09) to the increasing MELD score, Table 5.

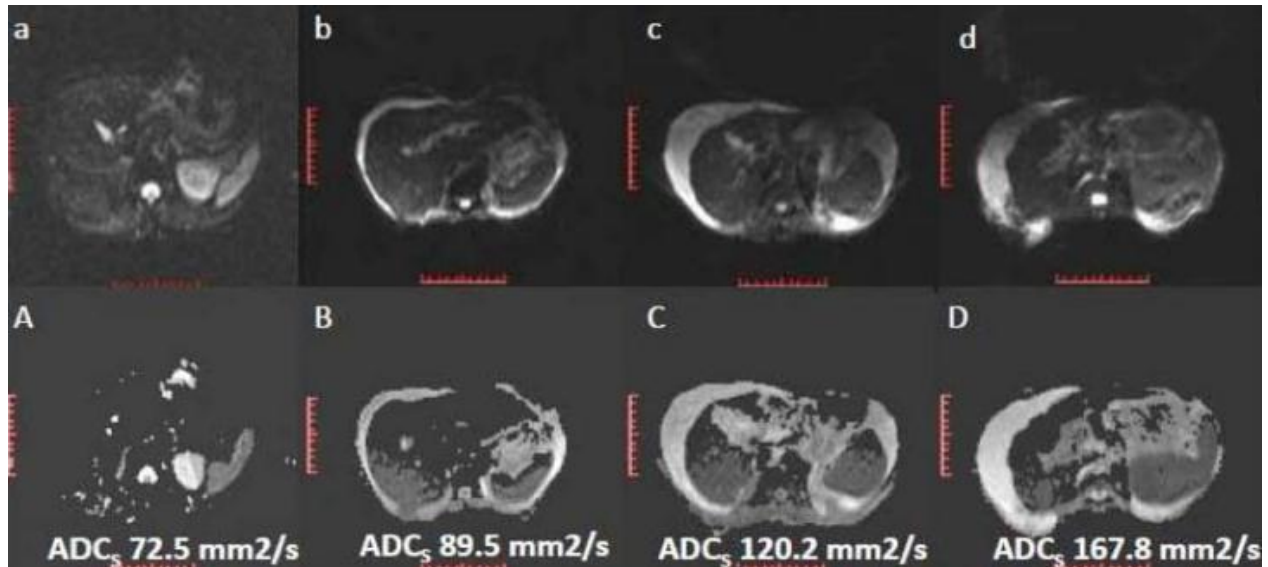


Fig 1:DWI and ADC Mapping of a Normal Study (a, A), Child Class A Cirrhosis (b, B), Child Class B Cirrhosis (c, C) and Child Class C Cirrhosis (d, D) with their respective Spleen ADC Values. ADCs- Spleen ADC

Discussion

In accordance to the recent studies, our initial part of the current study confirmed that liver ADC is significantly reduced in chronic liver disease patients compared with normal subjects. This can be attributed to the presence of fibrous tissue, which are collagenous tissue associated with restricted diffusion and subsequent diminished ADC values. However, we also found that spleen ADC is significantly increased in patients with chronic liver disease correlating to their splanchnic hyperaemia. However, this is in contradiction to the earlier reports except the one by Klasen et al, who found negative correlation between spleen and liver ADC in cirrhosis patients. Hence, in chronic liver disease patients, ADC liver decreases due to liver fibrosis and spleen ADC increases in view of splanchnic hyperaemia. One of the greatest hindrance to widespread adoption of DWI in the body is the lack of standardization. In prior studies, two different diffusion sequences were used with b values of 0, 150, 250 and $400 \text{ mm}^2/\text{s}$ and 600 and $800 \text{ mm}^2/\text{s}$, while in another study b values of 0 and $500 \text{ mm}^2/\text{s}$ were applied. As the b values increase ADC approaches the true diffusion coefficient, thus minimizing the influence of convective motion processes that are sensitive to diffusion-highlighting gradients, mainly perfusion in the randomly organized capillary network. As a general rule lower b values correspond to higher mean ADC, overestimated due to signal contribution from other intravoxel incoherent motions (mainly microvascular perfusion). On the contrary, higher b values lead to lower ADC values as a consequence of the gradient-enhanced signal

degradation that eliminates fast diffusion contributions. We took b value of 0, 300 and 500 for finding out the true diffusion coefficient[9]. Though our study had large cohort of patients to study and correlate spleen ADC to the severity of chronic liver disease and portal hypertension than previous studies, we had few limitations in our study. We did not use normalisation of the spleen ADC with a reference organ to have some standardization to the MRI protocol in view of technical difficulties. Secondly, it was difficult to get patients who were not on medications for portal hypertension. It will be interesting to study the treatment response on the spleen ADC using DWI[7-10].

Conclusion

In conclusion, our results show that spleen ADC values vary among patients with liver cirrhosis and control subjects. Furthermore, ADC values in the spleen correlated well with the severity of portal hypertension and not significantly with the degree of liver disease. Thus, the spleen might only be of limited value for normalization of liver ADC values to determine cirrhosis. ADC measurements may allow for non-invasive evaluation of portal pressure and even in assessment of treatment response.

References

1. Ong JP, Aggarwal A, Krieger D, et al. Correlation between ammonia levels and the severity of hepatic encephalopathy. *Am J Med.* 2003;114(3):188-93.

2. Trifan A, Cojocariu C, Sfarti C et al. Non-invasive evaluation of liver fibrosis in chronic hepatitis C. *Rev Med Chir Soc Med Nat Iasi*. 2012;116(1):135-8.
3. Denzer UW, Luth S. Non-invasive diagnosis and monitoring of liver fibrosis and cirrhosis. *Best Pract Res ClinGastroenterol*. 2009;23(3):453-60.
4. Do RK, Chandarana H, Felker E et al. Diagnosis of liver fibrosis and cirrhosis with diffusion-weighted imaging: value of normalized apparent diffusion coefficient using the spleen as reference organ. *AJR Am J Roentgenol*. 2010;195(3):671-6.
5. Enomoto M, Morikawa H, Tamori A et al. Noninvasive assessment of liver fibrosis in patients with chronic hepatitis B. *World J Gastroenterol*. 2014;20(34):12031-8.
6. Girometti R, Furlan A, Esposito G et al. Relevance of b-values in evaluating liver fibrosis: a study in healthy and cirrhotic subjects using two single-shot spin-echo echo-planar diffusion-weighted sequences. *J MagnReson Imaging*. 2008;28(2):411-9.
7. Sandrasegaran K, Tahir B, Patel A et al. The usefulness of diffusion-weighted imaging in the characterization of liver lesions in patients with cirrhosis. *ClinRadiol*. 2013;68(7):708-15.
8. Soyulu A, Kilickesmez O, Poturoglu S et al. Utility of diffusion-weighted MRI for assessing liver fibrosis in patients with chronic active hepatitis. *Diagn Interv Radiol*. 2010;16(3):204-8.
9. Tokgöz O, Unal I, Turgut GG et al. The value of liver and spleen ADC measurements in the diagnosis and follow up of hepatic fibrosis in chronic liver disease. *Acta Clin Belg*. 2014;69(6):426-32.
10. Hu XR, Cui XN, Hu QT et al. Value of MR diffusion imaging in hepatic fibrosis and its correlations with serum indices. *World J Gastroenterol*. 2014;20(24):7964-70.

Conflict of Interest: Nil

Source of support: Nil