

Comparison of proximal femur locking compression plate with dynamic hip screw in management of inter-trochanteric fracture

Samuel Lakra¹, Manju Boipai², Krishna Chander Birua^{3*}, Lal Bahadur Manjhi⁴, Vijay Kumar⁵, Govind Kumar Gupta⁶, Shashi Dinkar Minj⁷

¹Senior Resident, Department of Orthopedics, ICARE Institute of Medical Sciences and Research, Haldia, Purba Medinipur, West Bengal, India

²Assistant Professor, Department of Microbiology, Rajendra Institute of Medical Sciences, Bariatu, Ranchi, Jharkhand, India

³Assistant Professor, Department of General Surgery, ICARE Institute of Medical Sciences and Research, Haldia, Purba Medinipur, West Bengal, India

⁴Professor & Head, Department of Orthopaedics, Rajendra Institute of Medical Sciences, Bariatu, Ranchi, Jharkhand, India

⁵Associate Professor, Department of Orthopaedics, Rajendra Institute of Medical Sciences, Bariatu, Ranchi, Jharkhand, India

⁶Associate Professor, Department of Orthopaedics, Rajendra Institute of Medical Sciences, Bariatu, Ranchi, Jharkhand, India

⁷Associate Professor, Department of Anaesthesiology, Hazaribagh Medical College, Hazaribagh, Jharkhand, India

Received: 30-06-2020 / Revised: 22-08-2020 / Accepted: 24-08-2020

Abstract

Background: Intertrochanteric fractures are common in elderly population and pose a significant financial burden to the patients and family. Anatomically contoured proximal femur locking compression plate (PFLCP) is the latest addition to deal with these fractures, which creates an angular stable construct. It will theoretically lessen the risk of failure by screw cut-out and varus collapse, the common mode of DHS failure. **Materials & Methods:** This study was done to prospectively compare, the rate of union, complications, operative risks and functional outcomes in inter-trochanteric fractures treated with dynamic hip screw [DHS] and Proximal femur locking compression plate [PFLCP]. It also determined the effectiveness of PF-LCP in comparison to DHS in treatment of inter-trochanteric fractures. The data collected during the study of 30 cases of inter-trochanteric fractures, 15 cases were treated using PFLCP and other 15 group of cases were treated using DHS in the Department of Orthopaedics in Rajendra Institute of Medical Sciences, Ranchi from December 2012 to December 2014. **Results:** The functional outcome was measured with Harris Hip Score. In PFLCP group 7 (46.67%) cases had excellent result, 5 (33.33%) cases had good result, and 3 (20%) cases had fair result with no poor result. The mean score in PFLCP group was 86.4. In DHS group 7 (46.67%) cases had excellent result, 4 (26.67%) cases had good result, 2 (13.33%) cases had fair result and 2 (13.33%) cases had poor result. **Conclusion:** PFLCP is a good option for the management of inter-trochanteric fracture with high union rate and low rate of complication with high functional outcome and with a possibility that it can be done without C-Arm.

Keywords: Inter-trochanteric fracture, proximal femoral locking compression plate, dynamic hip screw, Harris Hip Score, outcome

This is an Open Access article that uses a fund-ing model which does not charge readers or their institutions for access and distributed under the terms of the Creative Commons Attribution License (<http://creativecommons.org/licenses/by/4.0>) and the Budapest Open Access Initiative (<http://www.budapestopenaccessinitiative.org/read>), which permit unrestricted use, distribution, and reproduction in any medium, provided the original work is properly credited.

*Correspondence

Dr. Krishna Chander Birua

Assistant Professor, Department of General Surgery, ICARE Institute of Medical Sciences and Research Haldia, Purba Medinipur, West Bengal 721645, India.

E-mail: krishnabirua@gmail.com

Introduction

Inter-trochanteric (IT) fractures are commonly seen in patients over 70 yrs of age. Incidence of these fractures has increased primarily due to increasing life span and more sedentary life style brought by urbanization. In younger population, IT fracture occurs due to high velocity trauma, where as in elderly population, it is most often due to trivial trauma. Inter-trochanteric fractures make up 45% of all hip fractures and are the major cause of death and disability in elderly [1, 2]. About 35-40% of these fractures are unstable three and four part configurations with displacement of posteromedial cortex. The failure rates of these unstable fractures fixed with sliding hip screws averages approximately 6-32% [1, 3, 4]. IT fractures can be managed by conservative or operative methods. Conservative methods were the treatment of choice until 1960 before the introduction of new fixation devices, as conservative methods resulted in higher mortality rates and complications like decubitus ulcer, urinary tract infections, pneumonia, thromboembolic complications. These methods have been abandoned. Conservative methods are now indicated for elderly person with high medical risk for anesthesia and surgery. Rigid internal fixation and early mobilization has been the standard method of treatment [5]. Inter-trochanteric fracture is the most frequently operated fracture type. Interestingly there has been no significant improvement or functional recovery over the past 50 years of surgical treatment [6]. Surgeon can control only the quality of reduction, choice of implant and its placement [7]. From the 1980s to 2000, sliding compression hip screw became the gold standard for hip fracture fixation. The complication rate for unstable fractures treated with a dynamic hip screw has shown to be as high as 3% to 15%. Primary or secondary varus collapse and hardware failure by “cut-out” of the femoral head screw are the most frequently reported complications [8]. Although postoperative fracture impaction of hips fixed with sliding screws may promote early healing, a high rate of union, and a low rate of hardware failure, excessive collapse is a problem that must be addresses [6]. The latest implant for management of intertrochanteric fracture is proximal femoral locking compression plate (PF-LCP; Synthes, West Chester, PA). Biomechanical studies have shown the PF-LCP to be stronger or equivalent to other fixation methods for fractures of the femoral neck and subtrochanteric femur fractures [9]. PFLCP has mechanical advantages of three-dimensional and

angular stable fixations. ‘Cut-out’ of the femoral head screw, which is the most frequently reported complication leading to implant failure in traditional implants was reduced with the PFLCP [10]. The PF-LCP thus fulfils the role of a fixed angle device and achieves the same or greater degree of variability sought with the dynamic condylar screw while avoiding the need for excessive bone removal [11]. Hence here we intended to study these two implants in inter-trochanteric fracture management and the clinical and functional outcome.

Material and Methods

After the patient with inter-trochanteric fracture was admitted to hospital all the necessary clinical details were recorded in proforma prepared for this study. After the completion of the hospital treatment patients were discharged and called for follow up at outpatient level, at regular intervals for serial clinical and radiological evaluation. As soon as the patient with suspected inter-trochanteric fracture was seen, necessary clinical and radiological evaluation was done and admitted to ward after necessary resuscitation and splintage with skeletal traction. The following investigations were done routinely on all these patients preoperatively.

Blood: Hb%, bleeding time, clotting time, blood grouping and cross matching, fasting and post prandial blood sugar, blood urea and serum creatinine X-ray: Pelvis with both hips AP view, chest X ray PA view in necessary patients. Associated injuries were evaluated and treated simultaneously. The patients were operated on elective basis after overcoming the avoidable anaesthetic risks. Post operatively patients were followed up at 6wks, 3 months, 6 months interval regarding pain, signs of sepsis and assessment with reference to Harris hip score and radiological assessment. The basis for the Harris Hip Score (HHS- Developed by Dr. William Harris, a prominent Orthopaedist in Massachusetts, the HHS is a tool for the evaluation of how a patient is doing after their hip is replaced. Based on a total of 100 points possible, each question is awarded a certain number of points based on how it is answered. Questions are further grouped into categories. The first category is pain. The second category is function. The third category is functional activities. Finally, the physical examination based on range of motion. The score is reported as 90-100 for excellent results, 80-90 being good, 70-79 fair, 60-69 poor, and below 60 a failed result. The final Harris Hip

Score was considered for comparison and evaluation of the functional results [12].

Pre Operative Planning

PFLCP

AP and lateral radiographs of the entire femur are necessary for complete evaluation. Traction radiographs and views of the contra-lateral femur are useful adjuncts in the planning process. Use the x-ray templates to aid in planning the procedure. Determine plate length and approximate screw lengths and instruments to be used [Fig. 1-5].

Dynamic Hip Screw

1. Length of Richard's screw: Length of Richard's screw is measured from tip of the head to the base of greater trochanter on AP view X-ray subtracting magnification.

2. Neck shaft angle: neck shaft angle is determined using goniometer on X-ray AP view on unaffected side.

3. Length of side plate: Length of the side plate is determined to allow purchase of at least 8 cortices to the shaft distal to the fracture.

Dynamic Hip Screw

The implant consists of lag screw, a compression screw barrel attached to the side plate. The lag screw is available in length from 60-110mm. About 19 mm compression screw allows a compression of 5mm. Barrel side plate available in angles of 125, 130, 135, 140 degrees and from 2-12 holes. The key and slot mechanism of the implant prevents rotational movements of the proximal fragments. About 4.5mm cortical screws are used to fix the side plate with shaft. Most proximal hole in the side plate allows insertion of 6.5 mm cancellous screw which can be used for fixation of lesser trochanter or a larger posterior-medial fragment. In our study we used lag screw of 60-110mm and a side plate that allowed a purchase of at least 8 cortices with shaft of femur and 125-135 degrees angled plate depending upon the neck shaft angle determined preoperatively. A minimum of 4 cortical screws were used to fix the side plate with the shaft.

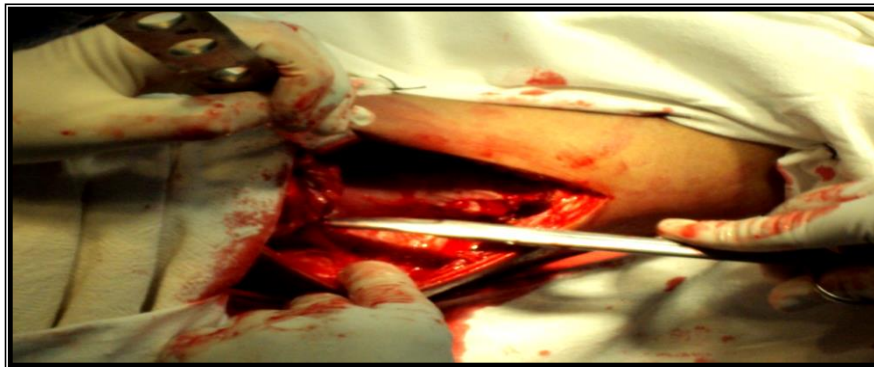


Fig 1: Exposing the proximal femur (intra-operative PFLCP)

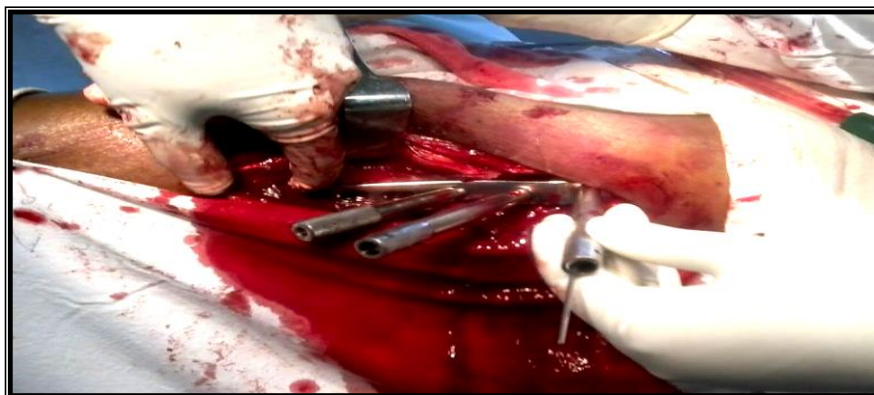


Fig 2: Placement of the plate over the lateral cortex of femur with drill sleeve (intra-operative PFLCP)

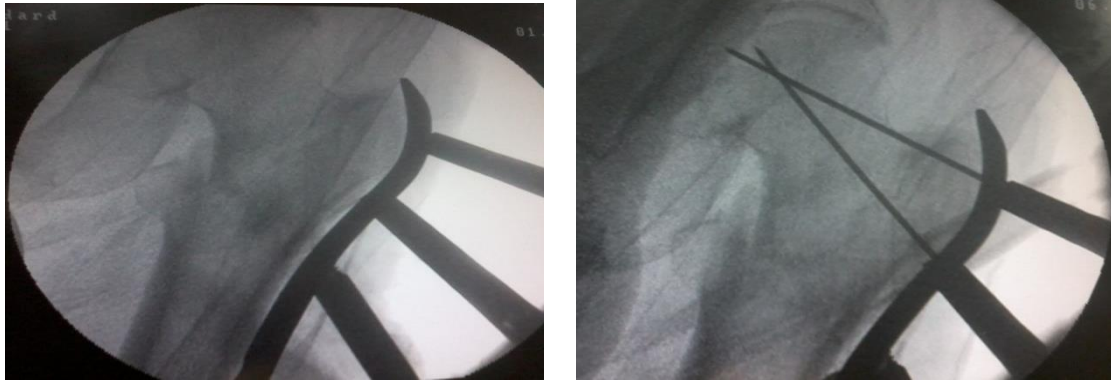


Fig 3 a/b: Confirming correct placement of plate and guide pin under C-arm

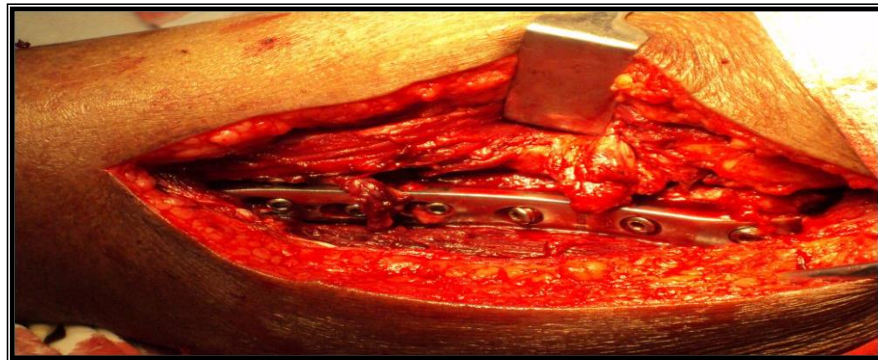

Fig 4: Fixation of plate with locking screws (PFLCP)

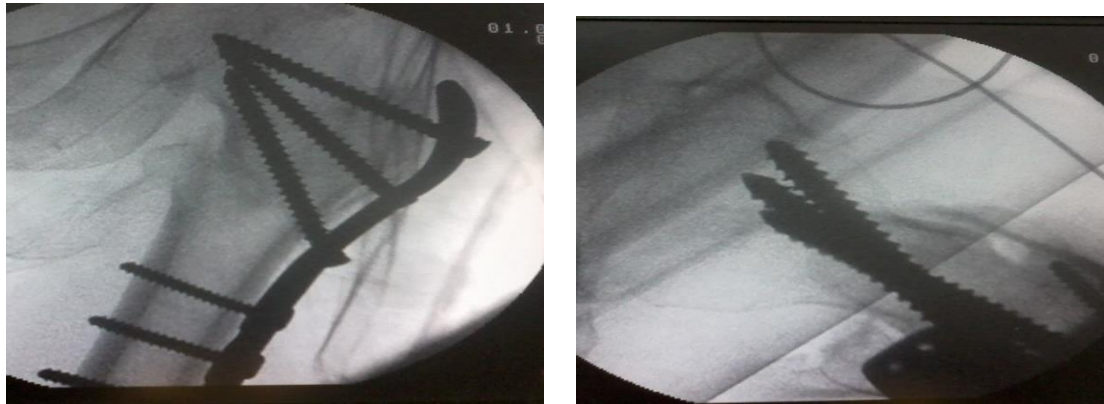


Fig 5: Confirmation of screw position and placement under C-arm in both AP and lateral views (PFLCP)

Results

The following observations were made from the data collected during the study of 30 cases of intertrochanteric fractures, 15 cases were treated using proximal femoral locking compression plate (PFLCP) and other 15 group of cases were treated using Dynamic

Compression Hip screw (DHS) in the Department of Orthopaedics in Rajendra Institute of Medical Sciences, Ranchi from December 2012 to December 2014.

Age Distribution

The study was limited to age group between 40-80 years. In the PFLCP group maximum cases were in the age group between 51-60 i.e. 6 cases (40%) and in DHS

group maximum number of cases were seen in age group 60-70 i.e. 6 cases (40%). Mean age group for PFLCP group was 60 years and mean age for DHS group was 61 years [Table 1].

Table 1: Age distribution among study participants

Age group	Number of cases		Percentage		Total cases	
	PFLCP	DHS	PFLCP	DHS		Percentage
40-50	3	3	20%	20%	6	20%
51-60	6	3	40%	20%	9	30%
61-70	4	6	26.67%	40%	10	33.33%
71-80	2	3	13.33%	20%	5	16.67%
Total	15	15			30	

Sex Distribution-In both groups there were more male cases than female cases [Table 2].

Table 2: Sex distribution

Sex	Number of cases		Percentage	
	PFLCP	DHS	PFLCP	DHS
Male	9	8	30%	26.67%
Female	6	7	20%	23.33%
Total	15	15	50%	50%

Nature of Injury-Fall was the major cause of fracture in both the groups [Table 3].

Table 3: Nature of injury

Nature of violence	Number of cases		Percentage	
	PFLCP	DHS	PFLCP	DHS
Fall	8	10	26.67%	33.33%
Road traffic accident	7	5	23.33%	16.67%
Total	15	15	50%	50%

Side Affected -In PFLCP there were 8 cases affecting right side and 7 affecting left side. In DHS group there were 6 cases affecting right side and 9 affecting left side [Table 4].

Table 4: Side affected

Side affected	Number of cases		Percentage	
	PFLCP	DHS	PFLCP	DHS
Right	8	6	26.67%	20%
Left	7	9	23.33%	30%
Total	15	15	50%	50%

Type of Fracture-Trochanteric fractures were classified according to BOYD and GRIFFIN Classification. Maximum numbers of cases were Type IV in PFLCP group and Type I in DHS group [Table 5].

Table 5: Type of fractures: Boyd & Griffin classification

Type of fracture	Number of cases		Percentage	
	PFLCP	DHS	PFLCP	DHS
Type I	3	6	20%	40%
Type II	2	4	13.33%	26.67%
Type III	3	3	20%	20%
Type IV	7	2	46.67%	13.33%
Total	15	15	100%	100%

Operative Time

The average operative time for PFLCP was 92.6 minutes(maximum time- 120 min, minimum time- 70 min) while for DHS was 54.6 minutes(maximum time- 90 min minimum, time- 45 min).

Blood Loss in Surgery

The average amount of blood loss in PFLCP was 376 ml (maximum- 480ml, minimum-300 ml) while in DHS was 267 ml (maximum- 330ml, minimum-200 ml)

Average Follow Up of Cases

The average follow up in the PFLCP group was 12.9 months and Range was from 8-18 months. The average follow up in the DHS group was 14.6 months and range was from 6-19 months.

Rate of Union

Union was defined radiologically with AP and lateral view of the affected Hip. Fracture was said to be united

when the fracture gap was bridged. Delayed union was considered if time taken to fill fracture gap exceeds 20 weeks. The Mean duration for union in PFLCP group was 17 Weeks with range from 12-24 weeks. The Mean duration for union in DHS group was 16.4 Weeks with range from 12-28 weeks.

Functional Scoring with Harris Hip Score

There were 7 excellent, 5 good and 3 fair results in PFLCP group with no poor results. In DHS group, there were 7 excellent, 4 good, 2 fair and 2 poor results. Although there were better functional results (Harris Hip Score) in PFLCP group when compared to DHS group the difference was not statistically significant with P value= 0.05. The mean Functional score (HHS) for PFLCP group was 86.4 and in DHS group was 83.4 [Table 6].

Table 6: Harris Hip score Functional scoring results

	PFLCP	DHS
Excellent	7	7
Good	5	4
Fair	3	2
Poor	0	2

Discussion

In 1950, Earnes Roll of Germany was the first to use sliding hips screws. In 1952 Schumpelick et al. described an implant design of a sliding cannulated system with side plate and reported telescoping of the implant with collapse of the fracture, leading to Trendelenburg gait in some patients [6]. In 1984, S.P. Mohanty and V. Chacko of Manipal, India, reported a comparative analysis of operative and nonoperative management of trochanteric fractures in 135 cases and found that the simple nonoperative methods was less superior than operative treatment [13].

In 1994, Blatter G et al studied about treatment of petrochanteric and subtrochanteric fractures of femur with DCS [14]. In 1995, Tepic & Perren reported about the new principle of fracture fixation based on what they called the internal fixator (PC-Fix: point contact fixator).The stability of this implant depends on the stiffness of the plate screw construct [6].

In 1995, an author reviewed 161 per-trochanteric fractures and the risk factors influencing outcome like age, fracture pattern and fracture level [15]. In 1996, the AO/ASIF introduced proximal femoral nail to reduce the risk of femoral shaft fractures associated with intramedullary devices. The PFN has certain modifications like 6mm antirotation screw, to increase rotational

stability 6 degree valgus bend in coronal plane, a narrow distal diameter, distal flexibility which minimizes the stress concentration and tension on femoral shaft [16].

In 2000 re-emergence of the importance of rotational instability prompted Gottfried to develop the PCCP (percutaneous compression plate) system which optimized the rotational stability of hip and minimized damage to the greater trochanter (lateral wall of femur) [6]. In 2007 Hasenboehler EA et al published on treatment of complex proximal femoral fractures with the proximal femur locking compression plate. The PFLCP represents a feasible alternative for the treatment of unstable inter- and sub-trochanteric fractures [11].

In 2010, Sun JF et al published minimally invasive treatment of inter-trochanteric fractures with locking compression plate in the elderly. Minimally invasive approaches with LCP could treat the elder inter-trochanteric fractures with the advantages such as minimal invasive, stable fixation and less blood loss. According to an evaluation standard of HUANG Gong-yi, the results were excellent in 20 cases, good in 4 cases and poor in 1 case [17]. In 2011 Glassner PJ, Tejwani NC published seven cases of failure of proximal femoral locking compression plate, Of the seven cases, two were acute peri-trochanteric fractures,

one was a peri-prosthetic fracture at the site of a prior hip fusion, one was an early failure of a compression hip screw, and three were non-unions. The failure mode was implant fracture in four cases and loss of fixation in three cases resulting from varus collapse and implant cut-out [18]. In 2011 Zha GC, Chen ZL, Qi XB, Sun JY studied a total of 110 patients (72 females and 38 males) with per-trochanteric femoral fractures who were subjected to PFLCP treatment. The mean age of the patients was 75 (48-93) years. The patients healed satisfactorily and had no complications, such as cut-out in most cases. However, there was one case of breakage of the implant and one case of non-union at the 3-month period during the follow-up check-up. The PFLCP can be a feasible alternative to the treatment of per-trochanteric fractures [10]. 2011 Luo XP, et al inter-trochanteric hip fractures treated with locking plate and DHS were retrospectively analyzed. The outcome measures collected for statistical analysis on the following aspects: operative time, blood loss, drainage, healing time, complications and Harris scores. There were no significant differences in the healing time, complications and Harris scores between two groups ($P > 0.05$), but there were significant differences in the operative time, blood loss, drainage between two groups ($P < 0.05$). Comparing with DHS group, the locking plate group was of shorter operative time, fewer blood loss and drainage [19]. In this study 30 patients with intertrochanteric fracture were selected and divided in two groups; 15 were treated with dynamic hip screw and other 15 were treated with proximal femur locking compression plate and their results were compared. The average operating time for PFLCP was 92.6 min while for DHS was 54.67 min. This observation was different from the observation made by Ma J et al (2012) [20] and Luo XP et al (2011) [19]. This difference may be due to the different technique. We used open reduction technique while they used the technique of percutaneous fixation. The average blood loss in PFLCP 376 ml and in DHS was 267 ml. This observation also differed from by Ma J et al (2012) [20] and Luo xp et al (2011) [19], due to difference in technique. Most common complication in PFLCP is failure to accommodate all 3 screws in neck and head. Three patients had varus malunion. The varus malunion was the most common mode of failure in Streubel PN (2012) [21] and also Glassner PJ (2011) [22]. The overall complication rate was less in case of PFLCP than in DHS. This was consistent with the observation made by Luo XP et al (2011) [19], Ma J et al (2012) [20] and Brandt SE et al (2002) [23]. The

mean duration of union was 17 weeks for PFLCP and 16 weeks for DHS. The mean functional score (Harris Hip Score) for PFLCP was 86.4 and DHS group was 83.4 but this difference was statistically not significant $P > 0.05$. This observation was similar to Luo XP et al (2011) [19]. Two cases of PFLCP were done without image intensifier (C- arm) due to technical difficulties. Due to pre-contoured plate, 2 screws were placed in neck and head of femur without C-arm and in both the cases screw were placed correctly. Thus PFLCP provide a feasible option for management of inter-trochanteric fracture without C- arm. In this study although statistically not significant, PFLCP had better functional outcome than DHS and thus PFLCP is better than DHS in management of inter-trochanteric fracture which can be even done without C-arm.

Conclusion

In our study we prospectively compared two implants in management of acute traumatic inter-trochanteric fractures. In our series of 30 patients with inter-trochanteric fractures, there were 15 cases treated with proximal femoral locking compression plate (PFLCP), group comprising 9 male and 6 female and 15 cases were treated with dynamic hip screw (DHS), group comprising 8 male and 7 female cases. The age group included in study was ranging from 40-80 years. Mean age for PFLCP group was 60 years; mean age for DHS group was 61 years. Cases were followed on regular interval with clinical, functional and radiological assessment. Mean follow up in PFLCP group was 12.9 months and in DHS group it was 14.6 months. The most common type of fracture in according to Boyd and Griffin Classification in PFLCP was type IV with 7(46.67%) cases and in DHS was type I with 6 (40%). The functional outcome was measured with Harris Hip Score. In PFLCP group 7 (46.67%) cases had excellent result, 5 (33.33%) cases had good result, and 3 (20%) cases had fair result with no poor result. The mean score in PFLCP group was 86.4. In DHS group 7 (46.67%) cases had excellent result, 4 (26.67%) cases had good result, 2 (13.33%) cases had fair result and 2 (13.33%) cases had poor result. The mean score in DHS group was 83.4, although the PFLCP had better results but the difference between the two groups was not statistically significant $P > 0.05$. PFLCP is a good option for the management of inter-trochanteric fracture with high union rate and low rate of complication with high functional outcome and with a possibility that it can be done without C-Arm.

References

1. Kyle RF, Gustilo RB, Premer RF. Analysis of six hundred and twenty-two intertrochanteric hip fractures. *J Bone Joint Surg Am.* 1979;61(2):216-21.
2. Zuckerman JD. Hip fractures. *N Engl J Med* 1996; 334:1519.
3. Mariani Eon, Rand JA. Nonunion of intertrochanteric fractures of the femur following open reduction and internal fixation. *Clin Orthop Relat Res* 1987; 218:81.
4. Haentjens P, Casteleyn PP, De Boeck H, Handelberg F, Opdecam P. Treatment of unstable intertrochanteric and subtrochanteric fractures in elderly patients. Primary bipolar arthroplasty compared with internal fixation. *J Bone Joint Surg Am.* 1989;71(8):1214-25.
5. Singh A K. Management of trochanteric fractures. *Indian J Orthop* 2006; 40: 100-2.
6. Robert W. Bucholz, Charles M. Court-Brown, James D. Heckman Rockwood and Green's fracture in Adults, 7th edition, volume 3, Pages 1597-1640.
7. S. Terry Canale, James H. Beaty. *Campbell's Operative Orthopedics*. Volume 3, 11th edition; Pages 3237-3285.
8. Simpson AH, Varty K, Dodd CA. Sliding hip screws: modes of failure. *Injury.* 1989; 20:227-231.
9. Aminian A, Gao F, Fedoriw W, et al. Vertically oriented femoral neck fractures: mechanical analysis of four fixation techniques. *J Orthop Trauma.* 2007; 21:544-548.
10. Zha GC, Chen ZL, Qi XB, Sun JY. Treatment of pertrochanteric fractures with a proximal femur locking compression plate. *Injury.* 2011 ;42(11) :1294-9.
11. Hasenboehler EA, Agudelo JF, Morgan SJ, Smith WR, Hak DJ, Stahel PF. Treatment of complex proximal femoral fractures with the proximal femur locking compression plate. *Orthopedics.* 2007 Aug;30(8):618-23.
12. Harris WH. Traumatic arthritis of the hip after dislocation and acetabular fractures: treatment by mold arthroplasty. An end-result study using a new method of result evaluation. *J Bone Joint Surg Am* 1969; 51: 737-55.
13. Chako V, Mohanty S P. Comparative analysis of operative and non-operative management of trochanteric fractures. *Indian Journal of Orthopaedics* 1984; 18(1):19.
14. Blatter G, Janssen M. Treatment of subtrochanteric fractures of the femur: reduction on the traction table and fixation with dynamic condylar screw. *Arch Orthop Trauma Surg* 1994;113(3):138-41.
15. Kamalahassan G, Kolla S. Management of Extracapsular Fractures of Hip with Proximal Femoral Nailing. *IOSR Journal of Dental and Medical Sciences (IOSR-JDMS)* 2016;15(6):75-78.
16. Daniel M, Noesberg G. Is proximal femoral nail a suitable implant for treatment of all trochanteric fractures. *Lipincott, Williams and Wilkins Inc,* 2005; 439: 221-227.
17. Sun JF, Li ZB, Shen YY, Han B, Deng L, Gu MQ. [Minimally invasive treatment of intertrochanteric fractures with locking compression plate in the elderly]. *Zhongguo Gu Shang.* 2010 ;23(5):337-9.
18. Glassner PJ, Tejwani NC. Failure of proximal femoral locking compression plate: a case series. *J Orthop Trauma.* 2011;25(2):76-83.
19. Luo XP, He SQ, Li ZA. [Case-control studies on locking plates and dynamic hip screw in treatment of intertrochanteric hip fractures]. *Zhongguo Gu Shang.* 2011;24(3):242-4.
20. Ma J, Xing D, Ma X, Xu W, Wang J, Chen Y, Song D. The percutaneous compression plate versus the dynamic hip screw for treatment of intertrochanteric hip fractures: a systematic review and meta-analysis of comparative studies. *Orthopaedics and Traumatology: Surgery and Research* 2012; 98(7): 773-783.
21. Streubel PN, Moustoukas MJ, Obremskey WT. Mechanical failure after locking plate fixation of unstable intertrochanteric femur fractures. *J Orthop Trauma.* 2013;27(1):22-8.
22. Glassner PJ, Tejwani NC. Failure of proximal femoral locking compression plate: a case series. *J Orthop Trauma.* 2011 Feb;25(2):76-83.
23. Brandt SE, Lefever S, Janzing HM, Broos PL, Pilot P, Houben BJ. Percutaneous compression plating (PCCP) versus the dynamic hip screw for pertrochanteric hip fractures: preliminary results. *Injury.* 2002;33(5):413-8.

Source of Support: Nil

Conflict of Interest: Nil