

## Lung Fibrosis in post COVID-19 patients: A hospital based comparative study

Shikha Rani <sup>1\*</sup>, Shashank Saurav <sup>2</sup>, Shivang Bharti <sup>3</sup>

<sup>1</sup> Senior Resident, Department of Radiodiagnosis, Patna Medical College and Hospital, Patna, Bihar, India

<sup>2</sup> Junior Resident, Department of Radiodiagnosis, Katihar Medical College, Katihar, Bihar, India

<sup>3</sup> MBBS, Institute of Medicine, India

Received: 21-05-2021 / Revised: 25-07-2021 / Accepted: 16-08-2021

### Abstract

**Background:** Lung fibrosis is being reported as one of the complications of COVID-19 pulmonary pneumonia, and it is one of the long-term complications of Covid-19. Fibrosis is associated with non-reversible lung dysfunction with reduced lung functions. The aim of this study is to diagnose, early detection and predict the prognosis of such patients whom may develop such serious complication, thus early introduction of anti-fibrotic drugs to save them for lung damage. **Methods & Results:** From April 2021 to May 2021, 100 patients in Patna Medical College, Bihar, who was confirmed COVID-19 by RT-PCR test, were evaluated by follow-up MDCT. A comparative study was done using follow-up data from the acquired CT images (different radiological signs and residual fibrotic changes). The cause for post-COVID-19 lung fibrosis is still unknown, however some predicting factors such as old age, cigarette smoking, high CT severity score, and long-term mechanical ventilation helps in predicting the prognosis of the patients. **Conclusions:** MDCT provides helpful assessment in post-COVID-19 pulmonary fibrosis and other post-covid related complications. Suitable aid like introduction of anti-fibrotic can be provided to the patients on time to avoid pulmonary complications.

**Key words:** COVID-19, Lung fibrosis, RT-PCR, Severity score.

This is an Open Access article that uses a fund-ing model which does not charge readers or their institutions for access and distributed under the terms of the Creative Commons Attribution License (<http://creativecommons.org/licenses/by/4.0>) and the Budapest Open Access Initiative (<http://www.budapestopenaccessinitiative.org/read>), which permit unrestricted use, distribution, and reproduction in any medium, provided original work is properly credited.

### Introduction

COVID-19 (coronavirus disease 2019) is an infectious disease caused by severe acute respiratory syndrome coronavirus 2 (SARS-CoV-2), a strain of coronavirus. The first cases were seen in Wuhan, China, in December 2019 before spreading globally, with more than 3 million deaths and 140 million cases now confirmed. The current outbreak was officially recognized as a pandemic by the World Health Organization (WHO) on 11 March 2020. [1].

Studies have shown that the most important risk factors for poor outcome are increasing age, male sex and obesity. Indeed obesity seems to trump all other comorbidities as a risk factor and its risk is not limited to inpatient populations [2].

The extent and severity of the long term respiratory complications of covid-19 infection remain to be seen, but emerging data indicate that many patients experience persistent respiratory symptoms months after their initial illness. COVID-19 complications may range from mild form of fatigue to serious forms requiring long-term Oxygen and ARDS. Most of the patients has recovered with no lung symptoms, many other patients suffer residual lung sequelae [8]. Till now, there is no proven treatment of post-COVID 19 lung fibrosis; the use of anti-fibrotics in the early acute phase of severe disease with ARDS may reduce fibrosis [9]. The aim of this study is to diagnose, early detection and predict the prognosis of such patients whom may develop such serious complication, thus early introduction of anti-fibrotic drugs to save them for lung damage.

medical therapy or even lung transplantation owing to pulmonary complications [3]. Patients recovering from covid-19 identifies potential respiratory problems including chronic cough, fibrotic lung disease, bronchiectasis, and pulmonary vascular disease [4]. COVID-19 leads to a variety of respiratory diseases with high occurrence of Acute respiratory distress syndrome (ARDS) [5]. Observational studies, has shown that some SARS-CoV-1 survivors have developed fibrotic pulmonary disease & restrictive lung abnormalities associated with impaired exercise tolerance [6]. Fibrosis has never been reported after H1N1 pneumonia. It is reported that approximately 30% of people with SARS has persisting lung abnormalities after their acute illness with fibrosis has been reported in about 8% of patients with SARS and 20% of patients with H7N9 influenza [7]. 140 million people have already been affected by COVID-19 in the course of this pandemic. The majority of the population has mild form of infection, 15% have a severe COVID-19 pneumonia, and 5% will progress t

### Methods

#### Study design

100 patients were taken in cross sectional study which include 50 males (50%) and 50 females (50%) with age range from 25 to 75 years old (mean age of 43.2 years old) were enrolled in this study in Patna Medical College, Bihar, during the period from April to May 2021. The male-to-female ratio was designed to 1:1. Patients with age range 60-75 years old were 30 patients, from 45-60 years old were 35 patients, and those ranging from 25-45 years old were 35 patients. All patients were subjected to full clinical data taking including age, sex, exposure history, and clinical complaint.

#### Consent from patients

A written consent was taken from all patients accepting to participate in our research work. All patients included in this research gave written informed consent to publish the data contained within this study.

#### Inclusion criteria

Patients who was confirmed diagnosed case of covid by polymerase chain reaction test (RT-PCR) with positive CT findings earlier, now follow-up chest CT was done with negative RT-PCR result to assess degree

\*Correspondence

**Dr. Shikha Rani**

Senior Resident, Department of Radiodiagnosis, Patna Medical College and Hospital, Patna, Bihar, India.

**E-Mail:** [drsikharanikmc@gmail.com](mailto:drsikharanikmc@gmail.com)

of recovery and residual fibrotic lung changes. Follow-up at 4–6 weeks and 9–12 weeks for patients with residual symptoms and/or residual lung fibrotic changes was done.

#### Exclusion criteria

Chronic Interstitial Lung Diseases, respiratory motion artifact, pregnant females, and patients with any other chronic medical condition such as Diabetes, hypertension, autoimmune disease etc, are not taken in the study group.

#### CT Imaging Findings

Initial CT-findings in COVID-19 cases include bilateral, multilobar ground glass opacification (GGO) with a peripheral or posterior distribution, mainly in the lower lobes and less frequently in the middle lobe. Consolidation superimposed on GGO as the initial imaging presentation is found in a smaller number of cases, mainly in the elderly population.

Septal thickening, bronchiectasis, pleural thickening, and subpleural involvement are some of the less common findings, mainly in the later stages of the disease. Pleural effusion, pericardial effusion, lymphadenopathy, cavitation, CT halo sign, and pneumothorax are some of the uncommon but possible findings seen with disease progression. There is much overlap of the CT-pattern of COVID-19 with other viral pneumonias. CT features like bronchovascular bundle distortion, fibrotic strips, traction bronchiectasis, architectural distortion, and interlobar septal thickening are suggestive of pulmonary fibrosis. CT was done after recovery from covid infection and having negative PCR results at 4–6 weeks interval and at 9–12 weeks. Two radiologists being blinded to the clinical data, assessed the CT image and analysed the CT severity score in each study.

#### CT severity score

The severity of the lung involvement on the CT correlates with the severity of the disease. [10, 11]. Visual assessment:

**Table.1: Clinical history of patients enrolled in our study**

Clinical history	Number of patients
Fever	70(70%)
Dry cough	55(55%)
dyspnea	50(50%)
Anosmia	30(30%)
Total	205

Some patients had more than one clinical history

#### Follow-up

CT chest was done after negative RT-PCR test to assess pulmonary fibrosis and lung changes. Follow-up at 4–6 weeks and 9–12 weeks for patients with residual symptoms and/or residual lung fibrotic changes was done. Most common presenting complaint was fever, seen in 70 patients (70%); 55 patients suffered from dry cough (55%), 50 patients had dyspnea (50%), and 30 patients had anosmia (30%) (Table 1). Some of the patients was also chronic smoker, about 40 patients used to smoke (40%). (More than 20 cigarettes/day for more than 10 years.) Post-COVID-19 pulmonary fibrosis was highly seen in patient ranging from 60-75-year age group (16/30 patients; 53.3%) followed by mild higher prevalence in 45–60-year age group (9/35 patients; 25%), than 25–45-year age group (6/35 patients; 17%). Patient who used to smoke cigarette showed much higher incidence of post-pulmonary fibrosis as compared to non-smoker. 22 patients develop post pulmonary fibrosis from 40 smokers who used to smoke (55%) (Fig. 3). The mild group of patients with (CT-SS of 1–17) (58 patients) showed less liability for post-COVID-19 fibrosis seen only in 12 patients (20.6%) whereas the severe group (CT-SS of 18–25) (42 patients) showed higher incidence of post-COVID-19 pulmonary fibrosis seen in 22 patients (52.38%). Our study reveals that male are more susceptibility of having post-COVID-19 lung fibrosis than females, as 19 males out of total 50 males was found to post-COVID-19 fibrosis (38%) in comparison to female patients where only 11 patients had post-COVID-19 lung fibrosis (22%), thus males are around 1.7 times more

The severity on CT can be estimated by visual assessment. This is the easiest way to score the severity. The CT images show a 25% involvement by visual assessment.

#### Severity score:

Another method is by scoring the percentages of each of the five lobes that is involved:

1. < 5% involvement
2. 5%-25% involvement
3. 26%-49% involvement
4. 50%-75% involvement
5. 75% involvement.

The total CT score is the sum of the individual lobar scores and can range from 0 (no involvement) to 25 (maximum involvement), when all the five lobes show more than 75% involvement. Some say that the percentage of lung involvement can be calculated by multiplying the total score times 4.

#### Ethical consideration

Written informed consent was taken from all patients with total protection to patient confidentiality were taken care.

#### Statistical analysis

Presented as medians and interquartile ranges and categorical variables are described as whole numbers with percentages in brackets.

#### Results

This cross-sectional study included 100 patients (50 males, 50 females) with age ranging from 25 to 75 years (mean age of 43.2 years), which was confirmed by RT-PCR test. They were then performed MDCT of the chest as a follow-up and to rule out other complications. CT was performed at initial presentation (after RT-PCR+ve report) & then follow-up chest scan was done

subjected to post-COVID-19 pulmonary fibrosis than females.

MDCT imaging features suggesting fibrosis were bronchovascular bundle distortion, fibrotic strips, traction bronchiectasis, architectural distortion, subpleural curvilinear atelectasis, and interlobular septal thickening.

#### Discussion

COVID-19 usually presents with fever (85%), cough (70%) and shortness of breath (43%), but abdominal and other symptoms are possible and the disease can be asymptomatic. Illness severity can vary from mild to critical. Most of mild to moderate cases have completely recovered by home isolation & only small proportion of severe cases gets complicated to Acute respiratory distress syndrome (ARDS) despite receiving adequate medical treatment [12].

Post-COVID lung fibrosis causes permanent pulmonary architectural distortion and irreversible pulmonary dysfunction [13].

Possible mechanism for fibrosis are: Cytokine storm caused by an abnormal immune mechanism may lead to initiation and promotion of pulmonary fibrosis. Epithelial and endothelial injury occurs in the inflammatory phase of ARDS due to dysregulated release of matrix metalloproteinases. VEGF and cytokines such as IL-6 and TNF $\alpha$  are also involved in the process of fibrosis. [14].

Our study was done initially at 3–4 weeks after onset of clinical symptoms and another at 10–12 weeks later for recording the progress of post-COVID-19 lung fibrosis. In our research, risk factors were correlated to predict possibility of development of post-COVID-19 pulmonary fibrosis such as advanced age, increased disease severity, sex, smoking, prolonged ICU admission and duration of mechanical ventilation, and CT severity score (CT-SS). Our study showed that age ranging from 60-75-year age group develop post-COVID-19 pulmonary fibrosis higher than any other age group patients (16 patients out of 30; 53%) who developed pulmonary fibrosis. This is matching to study by Wong et al. [15], who stated that older people are more likely to develop pulmonary fibrosis following

MERS. Low incidence of post covid lung fibrosis was noted in 45–60 year age group (9 patients out of 35; 25%), and 25–45-year age group (6 out of 35 patients; 17%); this was also noticed by Das K.M, et al. [16] that correlated age with MERS and SARS-CoV 2 pulmonary fibrosis development. Our study also reveals that males are 1.7 times more subjected to post-COVID-19 pulmonary fibrosis than females, as 19 males out of total of 50 males developed post-COVID-19 fibrosis (38%) as compared to female patients with only 11 patients with post-COVID-19 lung fibrosis (22%). This is caused by the effect of androgen which promotes the transcription of transmembrane protease, serine 2 gene that encoded protein primes the spike protein of SARS-Cov-2, thus impair antibody response and facilitate fusion of the virus and host cells [17]. Our study also showed that cigarette smoking has much higher chances of post-pulmonary fibrosis as compared to non-smokers. As from the 40 smoking patients, 22 developed post-pulmonary fibrosis (55%). That was stated by Vardavas C.I., et al. [18] that smokers are 1.4 times more likely to have severe symptoms of COVID-19 and 2.4 times more likely to need ICU admission and mechanical ventilation or die compared to non-smokers patients. CT severity score (CT-SS) also plays an important role in prediction of pulmonary fibrosis; in our study, we found that patients with mild CT-SS (1–17) (58 patients) showed less chances for post-

COVID-19 fibrosis, seen only in 12 patients (20.6%) whereas with severe group of CT-SS (18–25) (42 patients) showed higher chances of post-COVID-19 pulmonary fibrosis as in 22 patients (52.38%). That is matching with the study of Zhou F., et al. [19] who stated that increased disease severity is a reliable indicator of lung tissue destruction and correlates with mortality risk. According to the World Health Organization (WHO), 80% of SARS-CoV-2 infections are mild, 14% develop severe symptoms, and 6% will become critically ill. Potential antifibrotic therapies might have beneficial effects in the treatment of COVID-19 through a range of different mechanisms, such as preventing viral uptake and replication, inhibiting viral signalling, and through beneficial effects on the renin–angiotensin system [14]. Although there is clearly much work to be done before these drugs could be considered safe, let alone beneficial in the context of COVID-19, the medical community should be reassured that there is biological rationale to suggest that antifibrotic therapies might have potential as novel therapeutics for severe COVID-19.

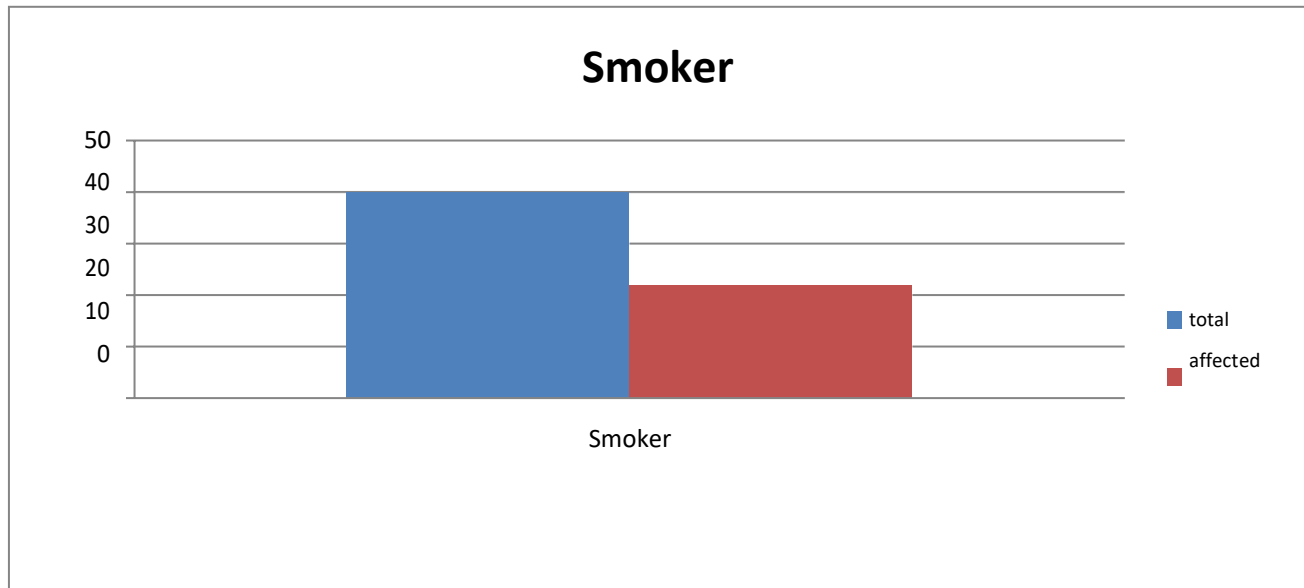
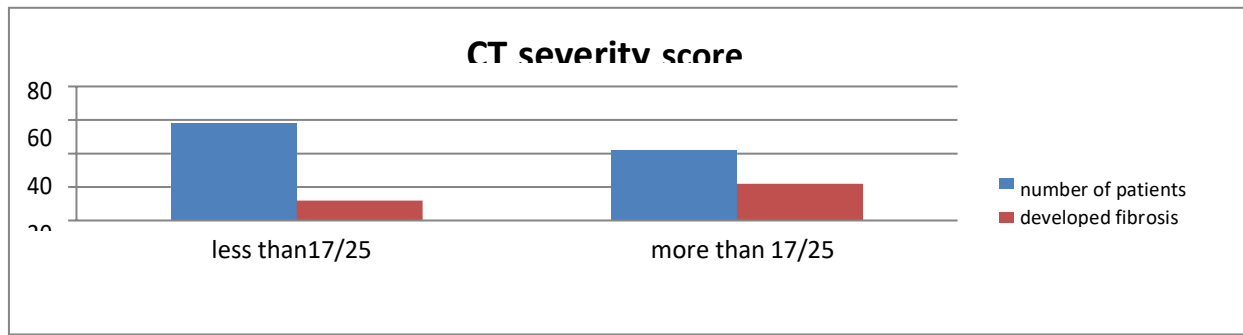
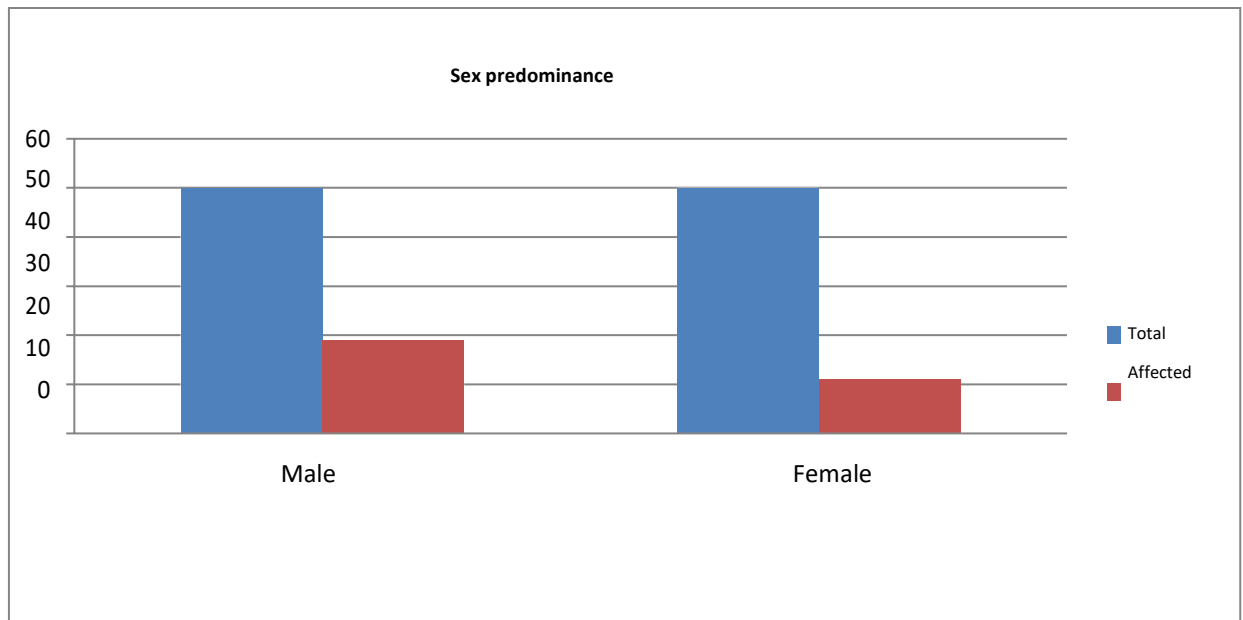


Fig 1: Cigarettes smoker showed much higher incidence of post pulmonary fibrosis than nonsmoking one



**Fig 2: CT severity score above 17/25 showed much higher incidence of post-COVID-19 pulmonary fibrosis**



**Fig 3: Males are 1.7 times more subjected to post-COVID-19 pulmonary fibrosis than females**

**Conclusion**

MDCT provides helpful assessment in post- COVID-19 pulmonary fibrosis and other post- covid related complications. Suitable aid like introduction of anti-fibrotic can be provided to the patients on time to avoid pulmonary complications.

**Abbreviations**

2019-nCoV: 2019 novel coronavirus; COVID-19: Corona virus disease; CT:

Computed tomography; CT-SS: Computed tomography severity score; H9N7: Influenza A virus subtype H9N7; MDCT: Multi-detector computed tomography; MSCT: Multi-slice computed tomography; PCR: Polymerase chain reaction; RT-PCR: Reverse transcriptase polymerase chain reaction; SARS-Cov-2: Severe acute respiratory syndrome coronavirus 2; WHO: World Health Organization ; ARDS: Acute respiratory distress syndrome;

**References**

- Peter M, Athol U, Jenkins RG (2020) Pulmonary fibrosis and COVID-19: the potential role for antifibrotic therapy. *Lancet* 138:805–815
- George P, Patterson C, Ak R (2019) Lung transplantation for idiopathic pulmonary fibrosis. *Lancet Respir Med* 7(3):271–282.
- Carfi A, Bernabei R, Landi F (2020) For the Gemelli against COVID-19 post-acute care study group. Persistent symptoms in patients after acute COVID-19. *J Am Med Assoc* 324(6):603–605.
- King CS, Nathan SD (2017) Idiopathic pulmonary fibrosis: effects and optimal management of comorbidities. *Lancet Respir Med* 5(1):72–84.
- Richeldi L, du Bois R, Ragu G et al (2014) Efficacy and safety of nintedanib in idiopathic pulmonary fibrosis. *N Engl J Med* 370(22):2071–2082.
- Jr King, Bradford WZ, Castro-Bernardini S et al (2014) A phase 3 trial of pirfenidone in patients with idiopathic pulmonary fibrosis. *N Engl J Med*

- 370:2083–2092
7. Zarir F, Priyanka K, Awatansh K et al (2021) Fibrotic interstitial lung disease occurring as sequelae of COVID-19 pneumonia despite concomitant steroids. *Lung India* 38(1):1–105
  8. Carsana L, Sonzogni A, Nasr A et al (2020) Pulmonary post-mortem findings in a series of COVID-19 cases from northern Italy: A two-center descriptive study. *Lancet Infect Dis* 1473-3099(20):30434–30435
  9. Wu C, Chen X, Yanping C et al (2020) Risk factors associated with acute respiratory distress syndrome and death in patients with coronavirus disease 2019 pneumonia in Wuhan. *China JAMA Intern Med* 180(7):934–943.
  10. Francone M, Iafate F, Gorgio M et al (2020) Chest CT score in COVID-19 patients: correlation with disease severity and short-term prognosis. *Eur Radiol* 4:1–10
  11. Pan F, Ye T, Sun P, Gui S, Liang B, Li L, Zheng D, Wang J, Hesketh RL, Yang L, Zheng C (2020) Time course of lung changes at chest CT during recovery from coronavirus disease 2019 (COVID-19). *Radiology* 295(3):715–721.
  12. Tale S, Ghosh S, Meitei SP et al (2020) Post-COVID-19 pneumonia pulmonary fibrosis. *Int J Med* 113(11):837–838
  13. Ademola S, Simon A, Oyeronke T et al (2020) Pulmonary fibrosis in COVID-19 survivors: predictive factors and risk reduction strategies. *Pulmon Med* 5: 1–10
  14. George PM, Wells AU, Jenkin RG et al (2020) Pulmonary fibrosis and COVID-19: the potential role for antifibrotic therapy. *Lancet Respir Med* 8(8):807–815. [https://doi.org/10.1016/S2213-2600\(20\)30225-3](https://doi.org/10.1016/S2213-2600(20)30225-3)
  15. Wong K, Antonio GA, Hui DS et al (2020) Severe acute respiratory syndrome: thin-section computed tomography features, temporal changes, and clinicoradiologic correlation during the convalescent period. *J Comput Assisted Tomogr* 28(6):790–795
  16. Sansone A, Mollaioli D, Ciocca G, Limoncin E, Colonnello E, Vena W, Jannini EA (2021) Addressing male sexual and reproductive health in the wake of COVID-19 outbreak. *J Endocrinol Invest*. 44(2):223–231.
  17. Lee EY, Singh R (2017) Follow-up chest radiographic findings in patients with MERS-CoV after recovery. *Indian J Radiol Imag* 27(3):342–349
  18. Vardavas CI, Nikitara K (2020) COVID-19 and smoking: a systematic review of the evidence. *Tob Induc Dis.* 2020; 18:20
  19. Zhou F, Yu T, Du R et al (2020) Clinical course and risk factors for mortality of adult inpatients with COVID-19 in Wuhan, China: a retrospective cohort study. *Lancet* 395(10229):1054–1062.

**Conflict of Interest: Nil Source of support: Nil**