

A technical note on the concomitant rotator cuff tendon repair and arthroscopic reduction of a missed/neglected anterior shoulder dislocation

Gadwal Azharuddin¹, Kondareddy Harikrishna Reddy², Aithagani Sandeep Kumar³

¹Post graduate, Department of Orthopedics, Narayana Medical College and Hospital, Chinthareddy Palem, Andhra Pradesh, India

²Professor, Department of Orthopedics, Narayana Medical College and Hospital, Chinthareddy Palem, Andhra Pradesh, India

³Professor, Department of Orthopedics, Narayana Medical College and Hospital, Chinthareddy Palem, Andhra Pradesh, India

Received: 29-11-2021 / Revised: 24-12-2021 / Accepted:02-01-2022

Abstract

Patients with neglected/missed anterior shoulder dislocation and an associated rotator cuff tear present a dilemma for the correct surgical approach that will facilitate a reduction of the dislocation and repair of the rotator cuff tear. This report describes an arthroscopic technique using standard arthroscopic portals to reduce neglected (3-6 weeks) anterior shoulder dislocation and repair the rotator cuff tendon. The arthroscopy is performed in a beach chair position using anterolateral and anteromedial portals for reduction of the shoulder dislocation. The same anterolateral portal is used as a viewing portal, and the anteromedial portal and an additional lateral portal are used for subsequent rotator cuff repair.

This is an Open Access article that uses a funding model which does not charge readers or their institutions for access and distributed under the terms of the Creative Commons Attribution License (<http://creativecommons.org/licenses/by/4.0>) and the Budapest Open Access Initiative (<http://www.budapestopenaccessinitiative.org/read>), which permit unrestricted use, distribution, and reproduction in any medium, provided original work is properly credited.

Introduction

Shoulder dislocation that is left untreated for 3 weeks or more has been termed as a neglected dislocation. Open reduction of the anterior dislocation may be needed if the condition is untreated for a few weeks; open reduction has been reported with satisfactory outcomes in the literature. In case of a neglected dislocation with a concomitant repairable rotator cuff tear that presents within the first 1 month, a reduction of the dislocation with a repair of the rotator cuff tendon is a reasonable and preferred option. If the reduction of the humeral head can be achieved arthroscopically, the subsequent repair of the rotator cuff may also be performed through the same arthroscopic approach, thus avoiding the hassle of open approach solely for the purpose of dislocation reduction. This arthroscopic approach is a significant advantage for those orthopaedic surgeons who are adept at repairing rotator cuff tears only arthroscopically. This technical report aims to describe an arthroscopic approach for reducing missed and neglected anterior shoulder dislocation (neglected for 3-6 weeks) and concomitant rotator cuff repair using our standard arthroscopy portals. Arthroscopic reduction of the anterior shoulder dislocation is helpful in the setting of a neglected/ missed (3-6 weeks) shoulder dislocation with a concomitant rotator cuff tear.

Patient Evaluation, Imaging, and Indications

Informed consent from the participant was obtained for this study. The duration of neglect of the shoulder dislocation should be ascertained because the arthroscopic technique of reduction is useful in first 36 weeks. Anteroposterior and axial X-rays should be done to evaluate the direction of the dislocated humeral head (posterior or anteroinferior). Magnetic resonance imaging (MRI) of the shoulder should be performed to note the type of cuff tear (posterosuperior or anterosuperior), to judge the reparability of the rotator cuff tendons,

*Correspondence

Dr. Kondareddy Harikrishna Reddy

Professor, Department of Orthopedics, Narayana Medical College and Hospital, Chinthareddy Palem, Andhra Pradesh, India

E-mail: dr.harikrishnareddy.k@gmail.com

and to establish the fatty infiltration stage of the rotator cuff muscles. The technique of arthroscopic reduction of chronic neglected shoulder dislocation and concomitant cuff repair is indicated in early (3-6 weeks old) neglected/missed anterior shoulder dislocation with a repairable rotator cuff tear.

Position and Set-Up

The procedure was performed on the right shoulder with the patient in the beach chair position. A 30arthroscope was used throughout the procedure

Step 1: Anterolateral Portal Visualization

The hand is draped separately, so that it is free to move, and no traction is used for the initial part of the arthroscopic surgery. The arthroscope is inserted through the anterolateral portal (D portal) for visualizing the glenoid and the glenohumeral space (Fig 1). Because the rotator cuff is already torn, the arthroscope enters directly in the glenohumeral space. An anterior dislocated humeral head is clearly visualized through this portal (Fig 2). Rotations of the hand can be used to confirm the associated humeral head rotation and its relationship with the glenoid cavity.

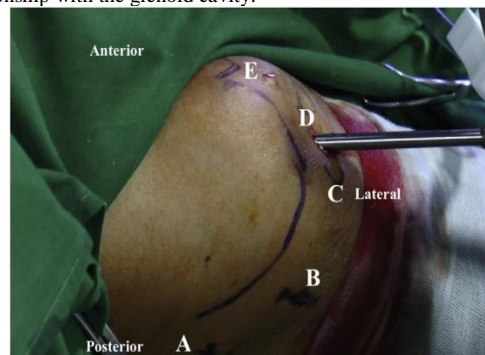


Fig 1. View from an overhead camera. Patient is in the beach chair position, and right shoulder is draped; no traction is used for the initial part of the surgery. Five portals are marked: posterior "A" portal, posterolateral "B" portal, mid-lateral "C"

portal, anterolateral “D” portal, and anteromedial “E” portal. The arthroscope is inserted through the “D” portal.

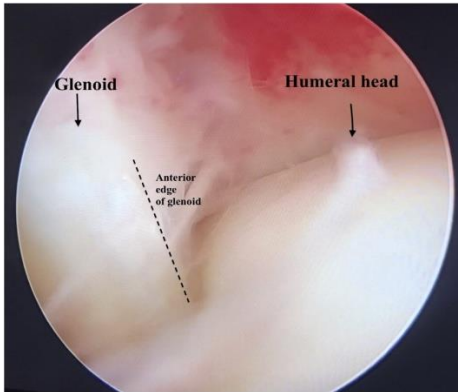


Fig 2. Arthroscopic view from the anterolateral “D” portal in a right shoulder. The anteriorly dislocated humeral head and its relationship with the glenoid cavity is clearly visualized as the head is seen dislocated anterior to the glenoid cavity.

Step 2: Insertion of the Curved Periosteal Elevator

A spinal needle is used to confirm the approach to the humeral head through the intended (E portal) anteromedial portal (Fig 3). After confirming the angle of approach, a curved periosteal elevator (A One Surgical, Gujarat, India) (Fig 4) is inserted through the anteromedial E portal (Fig 5). The curve of the periosteal elevator embraces the curvature of the humeral head (Fig 6).

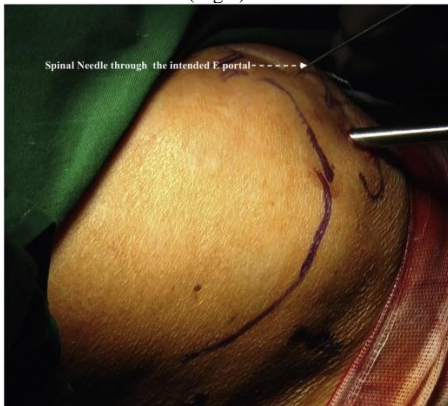

Fig 3. View of the right shoulder from an overhead camera. Patient is in the beach chair position. A spinal needle is passed through the intended anteromedial E portal to confirm the angle of approach to the humeral head



Fig 4. Picture of the curved periosteal elevator (A One Surgical, Ranawat, India) that is used for reducing the dislocated humeral head.

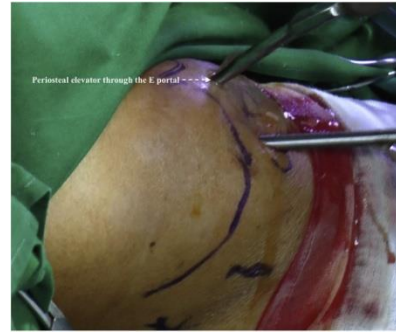

Fig 5. View of the right shoulder from an overhead camera. Patient is in beach chair position. The curved periosteal elevator is passed through the anteromedial E portal.

Step 3: Reduction of the Humeral Head

The hand is kept free, and gentle internal and external rotations of the humeral head and to free the humeral head of any adhesions. The periosteal elevator is used to exert gentle lateral pressure on the humeral head in the direction of the glenoid cavity. The humeral head is brought on the margin of the glenoid cavity by sustained gentle pressure and then reduced in the glenoid by pushing the head back inside the glenoid with the help of the periosteal elevator (Fig 6). The humeral head is clearly visualized, as it slides back in front of the glenoid cavity (Fig 7). The stability of the humeral head is checked by taking the hand through full external and internal rotation

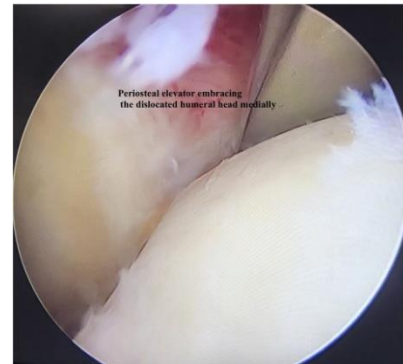


Fig 6. Arthroscopic view from the anterolateral D portal in a right shoulder: the periosteal elevator (that enters through the anteromedial E portal) embraces the humeral head medially.

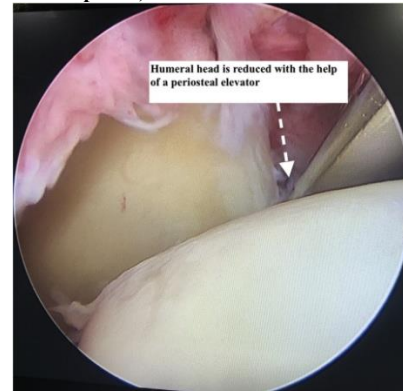


Fig 7. Arthroscopic view from the anterolateral D portal in a right shoulder: A laterally directed force is applied via the periosteal elevator. This lateral force relocates the humeral head in front of the glenoid cavity.

Step 4: Visualization Through the Posterior Portal and Subacromial Decompression

The rest of the surgery is performed as per the standard technique for rotator cuff repair. Traction (1.5 kg) to the upper extremity is employed at this stage and for the remainder of the surgery to open the subacromial space as per our standard protocol. The arthroscope is inserted through the posterior A portal (Fig 8), and the same anterolateral D portal can be used for inserting the shaver and the burr for performing a subacromial decompression and acromioplasty (Fig 9).

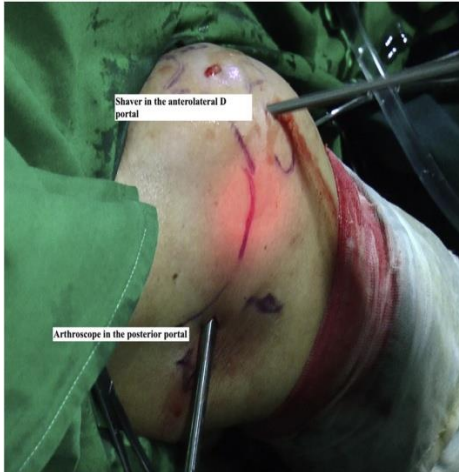

Fig 8. View of the right shoulder from an overhead camera; patient is in beach chair position. The arthroscope is inserted in the posterior A portal, and the shaver is inserted in the anterolateral D portal for performing a subacromial decompression and acromioplasty.

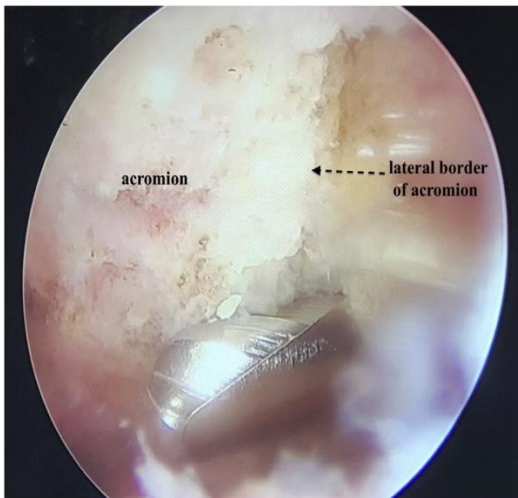


Fig 9. Arthroscopic view from the posterior A portal in a right shoulder; patient is in beach chair position: Acromioplasty and subacromial decompression is achieved with the shaver/burr through the anterolateral D portal.

Step 5: Visualization Through the Anterolateral Portal

In the next step, the arthroscope is inserted through the anterolateral D portal for visualizing the cuff tear end-on, and the same E portal and another lateral “C” portal are used for cuff repair instrumentation (Fig 10).

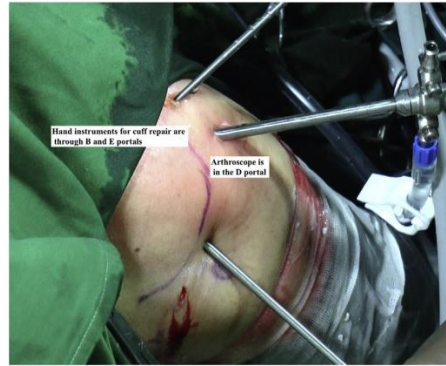

Fig 10. View of the right shoulder from an overhead camera; patient is in beach chair position. The arthroscope is inserted through the anterolateral D portal (viewing portal). The clever hook instruments are inserted through two portals (posterolateral B and anteromedial E portals) on either side of the viewing portal for the rotator cuff repair procedure.

Step 6: Double Row Rotator Cuff Repair

The arthroscopic visualization of the cuff tear (Fig 11) is achieved through the anterolateral D portal. An all-suture anchor is inserted medially; the corresponding sutures are passed through the cuff tendon (Fig 12). All of the sutures through the tendon are tied (Fig 13). All the suture limbs of the medial anchor are passed through a knotless anchor. This knotless anchor is inserted via the E portal through (Fig 14) a plastic cannula and inserted laterally below the tip of the GT (Fig 15), thus completing the double-row repair

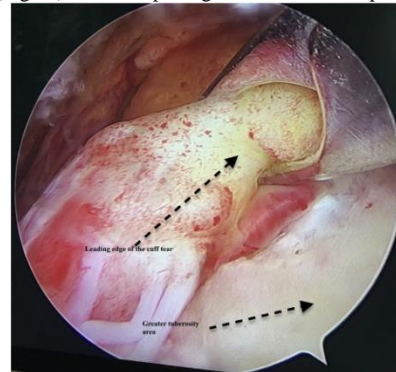


Fig 11. Arthroscopic view from the anterolateral D portal in a right shoulder; patient is in beach chair position: The reduction of the cuff tear is checked with the help of a grasper that is inserted through the anteromedial E portal.

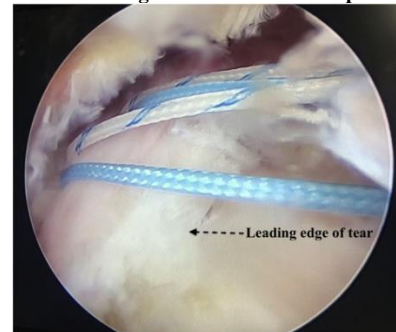


Fig 12. Arthroscopic view from the anterolateral D portal in a right shoulder; patient is in beach chair position: An anchor has been inserted medially, and all sutures from the medial anchor are passed through the rotator cuff tendon.

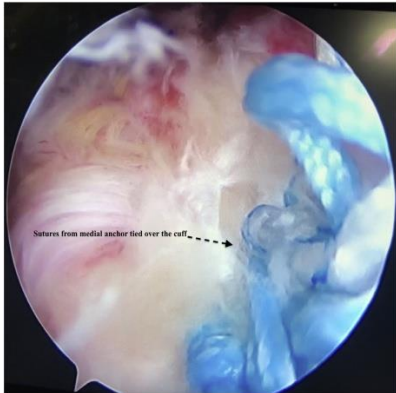

Fig 13. Arthroscopic view from the anterolateral D portal in a right shoulder; patient is in beach chair position: Sutures from the medial anchor that have been passed through the cuff tendon are tied over the rotator cuff, thus reducing the cuff tear to the greater tuberosity bed.

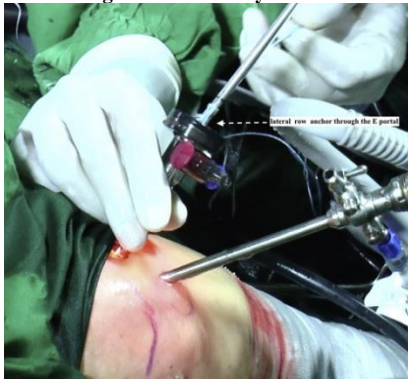

Fig 14. View of the right shoulder from an overhead camera; patient is in beach chair position: After the sutures of the medial anchor are tied over the cuff tendon, the suture limbs are passed in a lateral knotless anchor; this knotless anchor is inserted from the anteromedial E portal.

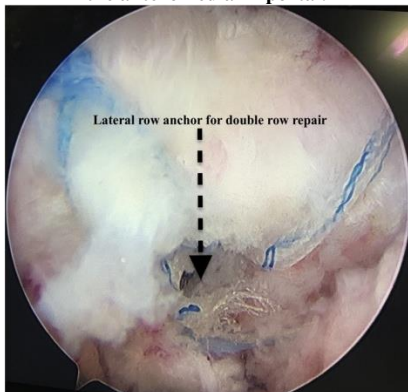


Fig 15. Arthroscopic view from the anterolateral D portal in a right shoulder; patient is in beach chair position: The knotless lateral row anchor with the suture limbs from the medial anchor is inserted laterally below the greater tuberosity tip.

Step 7: Closure

A final c-arm image of the shoulder at the end of the surgery is taken to confirm the reduction of the humeral head in the glenoid cavity (Fig 16).

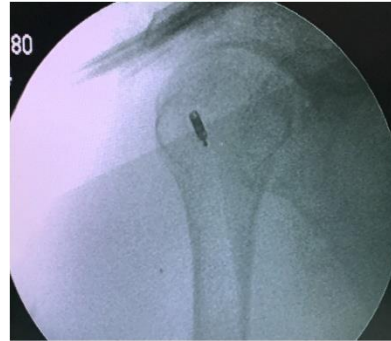

Fig 16. Photo of a final anteroposterior c-arm image of the right shoulder at the end of the procedure: The c-arm image confirms the reduction of the humeral head in the glenoid cavity.

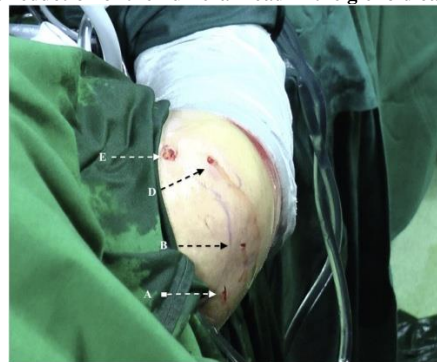

Fig 17. View of the right shoulder from an overhead camera; patient is in beach chair position: Overview of the four portals used in the surgery: posterior “A” portal, posterolateral “B” portal, anterolateral “D” portal, and anteromedial “E” portal. Figure 17 shows an overview of the 4 portals that were used in the entire procedure: portals D and E for humeral head reduction, portal A and D for subacromial decompression, and portals B, D, and E for the cuff repair. The portals are closed by sutures, and a shoulder sling is given for 4 weeks. The rehabilitation exercises of the shoulder are commenced after 4 weeks of the operation, as per our standard protocol.

Discussion

Closed reduction of shoulder dislocation may be attempted successfully until 1 week of the dislocation[4]. Closed reductions of chronic and missed dislocation of 1-3 weeks duration may be attempted with success in only some cases in the young age group[5]; but the forceful closed reduction maneuvers increase risks of fracture[6] and iatrogenic damage, especially in the elderly patient[7,8]. Vascular damage has been force in case of a neglected dislocation. Hence, closed reductions are better avoided in case of neglected anterior dislocations. An arthroscopic visualization of the humeral head during the reduction maneuver helps us judge the exact force needed to reduce the humeral head.

Moreover, we need to apply only gentle force to reduce the humeral head during arthroscopy. Because the force is directly being applied to the humeral head and not indirectly via pulling on the hand, excessive force is not necessary. The lateral portals used in the technique were according to our standard and regular techniques, and portals or instrumentation medial to the conjoint tendon were avoided. Therefore, no neurovascular structures are at risk in our technique of arthroscopic reduction.

The hand was kept free, and no traction to the hand was needed at any time point during relocation of the humeral head. The alternative open approaches for reduction and cuff repair have several disadvantages. A deltopectoral approach is suitable for reducing the dislocation, but the posterior retracted cuff tear is challenging to visualize and repair. A Mackenzie approach or a deltoid split approach is suitable for cuff

repair, but the access to the anteriorly dislocated humeral head will be limited, and hence, the dislocation will be challenging to reduce.

Arthroscopic approach for reduction of a locked posterior dislocation has been described in a recent report[10]. The present technique for arthroscopic reduction of anterior dislocation is less time-consuming than an open approach. It also avoids extensive dissections of the deltoid muscle, thus avoiding severe postoperative pain, a prolonged rest period for deltoid healing, and a lengthy rehabilitation period. The arthroscopic approach enables reduction and subsequent cuff repair in the same approach; hence, orthopaedic surgeons who are adept at arthroscopy techniques for cuff repair need not struggle with open techniques for cuff repair. The arthroscopic approach also enables us to appreciate the dynamic stability of the humeral head with rotations of the hand.

A c-arm exposure is also avoided as the rotations of the head are visualized clearly. However, it should be noted that an associated big rotator cuff tear facilitates the arthroscopic reduction of the dislocation. A direct entry in the joint via the anterolateral portal is easily performed because of the rotator cuff tear.

The author also wants to emphasize that this approach may be helpful in patients with a few weeks of missed dislocation (3-6 weeks). A dislocation that has been missed for a few months to years may present additional challenges of severe adhesions and contractures of the anterior and posterior capsules. In summary, the arthroscopic reduction of missed anterior dislocation is an effective, fast, and reasonable approach that can be used safely in elderly patients with a missed anterior dislocation and an associated rotator cuff tear.

Conflict of Interest: Nil Source of support: Nil

References

1. Sahu D, Rathod V, Phadnis A, Shyam A. Results and complications of head-preserving techniques in chronic neglected shoulder dislocation: a systematic review. *J Shoulder Elb Surg*2021;30:685-694.
2. Rowe CR, Bertram Z. Chronic unreduced dislocations of the shoulder. *J Bone Jt Surg*1982;64:494-505.
3. Jaramillo Quiceno GA, Arroyave Rivera SA, Ortiz MM. Acute massive rotator cuff rupture with posterior shoulder dislocation: Arthroscopic novel repair of a rare injury. A case report. *J ISAKOS*2021;6:375-379.
4. Goga IE. Chronic shoulder dislocations. *J Shoulder Elb Surg* 2003;12:446-450.
5. Schulz TJ, Jacobs B, Patterson RL. Unrecognized dislocations of the shoulder. *J Trauma Inj Infect Crit Care*1969;9: 1009-1023.
6. Pan X, Yao Y, Yan H, et al. Iatrogenic fracture during shoulder dislocation reduction: Characteristics, management, and outcomes. *Eur J Med Res*2021;26:73.
7. Ranawat AS, Difelice GS, Suk M, Lorich DG, Helfet DL. Iatrogenic propagation of anterior fracture-dislocations of the proximal humerus: case series and literature review with suggested guidelines for treatment and prevention. *Am J Orthop*2007;36:E133-E137.
8. Atoun E, Narvani A, Even T, et al. Management of first- or without Bristow-Latarjet procedure. *Orthop Surg* time dislocations of the shoulder in patients older than 2020;12:1478-1488.